



Archaeological fieldwork at the Medieval and Early Modern churchyards in Nõo, Pilistvere and Põltsamaa

Martin Malve

Tartu Ülikool, ajaloo ja arheoloogia instituut, arheoloogia osakond (University of Tartu, Institute of History and Archaeology, Department of Archaeology), Jakobi 2, 51014 Tartu, Estonia; martinmalve@gmail.com

INTRODUCTION

In the recent years, more and more archaeological fieldwork has been carried out due to the renovation and reconstruction of rural churches (e.g. Kose churchyard, Malve *et al.* 2014a). Local congregations apply actively for funding to various programs (e.g. the program ‘Conservation and development of places of worship’¹; PRIA², etc.) and for donations in order to restore and make churches more attractive also to tourists. In most cases the archaeological survey is instigated by the accompanying soil works (e.g. trenches for pipelines) which affect also the undisturbed cultural layer at the churchyards (burials and remains of the constructions). Investigations have brought a lot of new and interesting information about the inhabitants of the parishes. The paper gives an overview of three field surveys conducted in connection with the soil work at the churchyards in central and south Estonia (Fig. 1). The main focus is on the analysis of the burials; emphasis is put to the paleopathological aspect of the human remains.

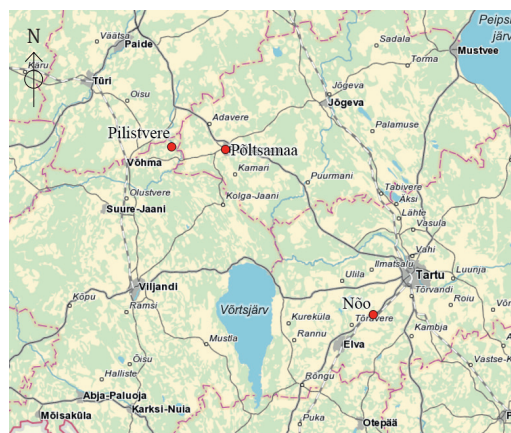


Fig. 1. Investigated Medieval and Early Modern parish churchyards in 2015.

Jn 1. 2015. a uuritud kesk- ja varauusaegsed kirikiaiad.

Drawing / Joonis: Raido Roog

NÕO CHURCHYARD

Nõo St Lawrence church is one of the oldest rural churches in the Brick Gothic region of mainland Estonia. It was likely built already in the end of the 13th century and the first written sources mentioning the priest in Nõo date to the early 14th century (Alttoa 1999, 84). A small-scale fieldwork took place in 1998 when during the installation of a communication cable, a few human bones, a fragment of an iron buckle³ and some debris were found

¹ <http://www.muinas.ee/puhakoda>, visited 07.08.2016.

² Estonian Agricultural Registers and Information Board, a government agency administrating several aid schemes.

³ TÜ 694.

(Tvauri 1999, 138). In 2015 a pipeline was installed into the church. The trench for the pipes was drilled under the burial layer (Malve 2016a). The archaeological research covered the ends of the drilling holes (altogether five test pits) and a small excavation plot (Fig. 2).

19 *in situ* burials were found (Table 1), among which 18 were unearthed. Also, numerous commingled bones were collected.⁴ The buried lay on their backs in a stretched position. The heads of the deceased were directed to the west. The depth of the graves varied from 0.7 to 1.4 m from the ground level, the majority of them being between 0.7 and 1.1 m from the surface. The soil – red clay typical to Tartu region – was difficult to dig and this can be the reason why the depth of the burials was relatively small and most of the earlier skeletons were disturbed

Table 1. Osteological age and sex of the recorded skeletons from Nõo churchyard.

Tabel 1. Nõo kirikaast leitud luustike osteoloogiline vanus ja sugu.

Compiled by / Koostanud: Martin Malve

Burial no. / Matus nr	Sex / Sugu	Age / Vanus	Pathologies / Patoloogiad	Stature / Kehakasv
1	♂	35–45 y / a	Osteochondrosis of cervical vertebrae; spondyloarthritis; unfused arch of the atlas. Teeth: slight dental calculus; medium alveolar reduction; <i>ante mortem</i> lost teeth; dental caries; periapical lesions	-
2	?	2 y / a ± 8 m / k	-	-
3	♂	35–45 y / a	Osteochondrosis of cervical vertebrae; spondyloarthritis; spondylosis. Teeth: slight dental calculus; remarkable alveolar reduction; <i>ante mortem</i> lost teeth; enamel hypoplasia; periapical lesions	-
4	♂	25–40 y / a	-	174.2±3.27 cm
5	♂	Adult / Täiskasvanu	-	-
6	?	2–4 y / a	-	-
7	♀	17–21 y / a	Lumbarisation of the first sacral vertebrae	157.1±4.45 cm
8	♂	15–18 y / a	Teeth: slight dental calculus; enamel hypoplasia	-
9	?	Adult / Täiskasvanu	Schmorl's nodes	-
10	♀	40–45 y / a	Schmorl's nodes	157.0±3.72 cm
11	?	7–11 y / a	Teeth: slight dental calculus	-
12a	♀	40–45 y / a	Spondylosis and osteoarthritis	152.5±3.27 cm
12b	♀?	Adult / Täiskasvanu	-	-
13	?	Adult / Täiskasvanu	-	-
14	♂	40+ y / a	<i>Peri mortem</i> cut wound on the occipital bone; ivory osteoma on cranium; left clavicle with healed fracture on the lateral end; osteochondrosis of cervical vertebrae; spondyloarthritis; spondylosis; Schmorl's nodes. Teeth: slight dental calculus; remarkable alveolar reduction; <i>ante mortem</i> lost teeth; enamel hypoplasia; periapical lesions	172.9±3.27 cm
15	♂?	40+ y / a	Periostitis on the surface of the diaphysis of the left tibia; Osteoarthritis on left knee joint	-
16	♂	35–45 y / a	Metopic suture still present; two ivory osteomas on cranium; spondyloarthritis; spondylosis; compression of the XI and XII thoracic vertebrae; Schmorl's nodes. Teeth: medium dental calculus; medium alveolar reduction; <i>ante mortem</i> lost teeth; dental caries; enamel hypoplasia; periapical lesions	170.3±3.27 cm
17	♂	40+ y / a	Periostitis on the surface of left fibula; osteoarthritis on knee joints	-
18	?	Adult / Täiskasvanu	-	-
19	?	6–12 y / a	Unfused arch of the fifth lumbar vertebra	-

⁴ After the osteological analysis of the skeletons and stray bones the human remains were reburied in the Nõo churchyard. Only some rare cases of pathologies and the bone samples are preserved in the osteological collections of the Department of Archaeology of TÜ.

by later burials (Fig. 3). The coffin wood was observed only in one case (skeleton no. 13) and the body position of three skeletons (skeletons nos. 4, 16 and 17) also enabled to assume burying in coffins. The density of the burials was surprisingly small – burials were situated mostly in one or two layers, in one case up to four layers. During the fieldwork it was established that the burial ground covered the area partly outside of the present-day churchyard, extending to the neighbouring plots north and west of the church (Fig. 2) where human bones were discovered during land cultivation and house building.

Skeletons

The osteological analysis revealed 14 adults and five subadults.⁵ The overall survival of the bones was good, but there were some variations between individual burials. However, many skeletons had suffered truncation, mainly as the result of grave digging and nature of the soil.

Diseases caused by ageing were common (Table 1): wearing of the limb joints (osteoarthritis) and the degenerating of the vertebral column (osteocondrosis of the cervical vertebrae, spondyloarthritis and spondylosis). The most frequent pathologies were observed on teeth (dental caries, dental calculus, alveolar reduction, periapical lesions). Periostitis was recorded on tibiae and fibulae of two adult males. Periostitis is a common finding in most archaeological groups and is most often found in lower leg (in tibiae and fibulae) (Connell & Miles 2010, 43–44). Periostitis is an inflammatory condition of the outer layer of a bone (Stirland 2009, 23). It can be caused by specific or non-specific infection, its aetiology is generally uncertain. These could be associated with stress, minor trauma or varicose vein problems (Cowie *et al.* 2008, 52).

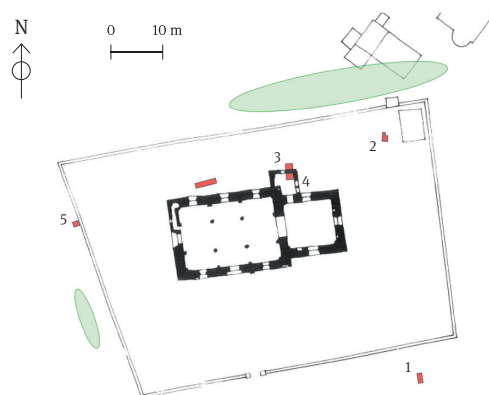


Fig. 2. Archaeologically excavated drilling holes (pits 1–5) and a small excavation plot (marked with squares) with an area where human remains have been found (marked with ovals) in Nõo churchyard.

Jn 2. Nõo kirikaia arheoloogiliselt avatud augud (1–5) ja väike kaevand (tähistatud ruutudega) ning alad, kust on leitud inimluid (tähistatud ovaalidega).

Drawing / Joonis: Raido Roog



Fig. 3. Cleaned burials nos. 11, 12a, 12b, 13, 14, and 15 in Nõo churchyard.

Jn 3. Nõo kirikaia välja puhastatud matused nr 11, 12a, 12b, 13, 14 ja 15.

Photo / Foto: Martin Malve

⁵ The sex of the burials was determined according to the morphological traits on the pelvis and cranium (Buikstra & Ubelaker 1994, 16–20) and the maximum length of the long bones (Garmus & Jankauskas 1993, 6–8) and tarsal bones (Garmus 1996, 2). The age at death was determined according to the changes in pubic symphyseal face (Todd 1920; 1921; Brooks & Suchey 1990), wearing of the teeth (Brothwell 1981, 72) and age-caused changes on the limb joints (Ubelaker 1989, 84–87). The age of subadults was determined by examining the development and eruption of the teeth (Ubelaker 1989, 63) the epiphyseal fusion (Schaefer *et al.* 2009) and the length of the long bones (Allmäe 1998, 183). Pathological conditions were identified with the aid of Ortner & Putschar (1985) and Roberts & Manchester (2012). On teeth the degree of dental calculus and alveolar reduction was estimated (Brothwell 1981, 155 and fig. 6.14 a, b). Stature was calculated according to the formule of Trotter and Gleser (Trotter 1970) using measurements of the long bones. The osteological material of Pilistvere and Põltsamaa church was analysed by using the same methods as in Nõo.

Schmorl's nodes were found on the thoracic and lumbar vertebrae of four middle-aged or older adults (two males, one female, one adult with undetermined sex; see Table 1). Schmorl's nodes are small rounded lesions on the surfaces of the vertebral bodies (Faccia & Williams 2008, 30). Schmorl's nodes are often related to physical stress and trauma, but also congenital defects of the spine must be taken into account (*ibid.*). Ivory osteomas were documented on frontal and parietal bones of two crania. It is a benign tumour of bone tissue which usually does not cause any ailments (Roberts & Manchester 2012, 255).

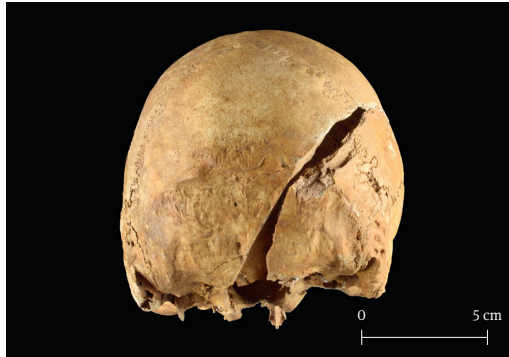

Fig. 4. Unhealed *peri mortem* blade wound on the skull.

Jn 4. *Paranemata surmaaegne terahaav koljul.*

Photo / Foto: Martin Malve

In addition to the pathologies related to diet and everyday activities, the back of the head of an adult male (skeleton no. 14) bore a cut mark caused by a sharp object. The lower part of the occipital bone of a male older than 40 years showed a linear cut trace approximately 7.6 cm long (Fig. 4). The person also had a healed fracture of the lateral end of the left clavicle, spondyloarthritis on vertebral column and Schmorl's nodes on the thoracic vertebrae connected to both physical stress and ageing. The cut mark was of the same colour as the rest of the cranium, confirming that the wound was *peri mortem*. Since the lesion was thin and with a polished surface and sharp edges and the blow had not dam-

aged other parts of the skull it is likely that the lethal trauma was caused by a bladed object (e.g. sword). The blade had penetrated the cranium and injured the brain. These kinds of traumas usually happen in eye-to-eye hand-to-hand combat and they are usually located on frontal and parietal bones (Manchester 1983, 59–60). The location of the wound on the back side of the head refers to a hit from behind. Traces of interpersonal violence are not easily recognisable in the archaeological record; mostly a single case occurs in an osteological series (e.g. the cemetery under the Triumph bastion in Narva; see Ööbik *et al.* 2015, 187). The only presently known cases of *peri mortem* blade injuries from rural churchyards are from Kose, where two crania wore fatal wounds (Malve *et al.* 2014b). The osteological analysis of the human remains found from parish churchyards will definitely reveal more such examples in the future.

In summary, the pathologies discovered on the bones from Nõo are typical to the Medieval and Early Modern Times cemeteries in Estonia. Dental disease appears to have been the most chronic illness to affect the major part of the group.

Finds

Several artefacts were collected both from the burials and from the mixed soil. A simple round brooch with a rounded cross section was found as a stray find; the arch was surrounded by the needle (Fig. 5: 1). Since the brooch is quite robust and represents a relatively rare type, it may date from the Medieval Period.⁶ Also three glass beads (Fig. 5: 2–3), an iron buckle⁷ and a simple closed finger-ring⁸ originate from the graves disturbed by later burials.

⁶ Pers. comm. Heiki Valk 21 July 2016.

⁷ TÜ 2520: 15.

⁸ TÜ 2520: 1.

One female burial (skeleton no. 10) had a knife placed near the right pelvic bone; another female burial (skeleton no. 12a) had a spiral ring and a penannular brooch (Fig. 5: 4–5), the latter is similar to the 14th – 15th-century brooches found from the Siksälä burial ground (Valk *et al.* 2014, 56: burial XXXV). A belt buckle with a needle⁹ was unearthed from the left ilium of an adult male (skeleton no. 13). Fragments of spiral tubes were found above the sternal parts of the clavicles (Fig. 5: 6–7) of skeleton no. 14 (a single fragment was also found inside of the left part of the rib cage next to the tenth costa; Fig. 5: 8). In addition to the artefacts connected to the burials, numerous glass sherds of the church windows and a fragment of a lead window frame were unearthed.

Cross graffiti

Two cross marks were discovered on the outer wall of the church chancel (Fig. 6) which were exposed after the plaster had fallen off. The crosses were *ca.* 10 cm in height and were carved in the mortar between the boulders, indicating that they were made before the plastering of the chancel. Similar carved crosses have been detected only on the outer surfaces of the Medieval and Early Modern rural churches all over Estonia (e.g. the churches of Tarvastu, Karula, Kadrina *etc.*) but mostly on the portals and corners (Johanson & Jonuks 2015, 128).

PILISTVERE CHURCHYARD

The church of St Andrew in Pilistvere was founded during the third quarter of the 13th century (Alttoa 1995, 18). The building has been repeatedly damaged in the 17th and 18th century and was rebuilt in 1762 (*ibid.*). Previous archaeological excavations in the churchyard took place in 1999 when Heiki Valk conducted investigations after a cable trench was dug without permission from the




Fig. 5. Artefacts collected from Nõo Churchyard: 1 – a simple round brooch, 2, 3 – glass beads, 4 – a spiral ring, 5 – a penannular brooch, 6 – a spiral tube next to the right clavicle, 7 – a spiral tube next to the left clavicle, 8 – a spiral tube inside the left rib cage. 1–3 – mixed soil, 4, 5 – burial no. 12a, 6–8 – burial no. 14.

Jn 5. Nõo kirikaast kogutud esemed: 1 – vitssõlg, 2, 3 – klaasist helmed, 4 – spiraalsõrmus, 5 – hoburaudsõlg, 6 – spiraalтору parema rangluu juurest, 7 – spiraalтору vasaku rangluu juurest, 8 – spiraalтору vasaku rinnakorvi poole seest. 1–3 – segatud pinna-sest, 4, 5 – matus nr 12a, 6–8 – matus nr 14.

(TÜ 2520: 1, 7, 8, 17, 18, 20, 21, 22.)

Photo / Foto: Martin Malve



Fig. 6. Cross graffiti on the outer wall of the chancel of the Nõo church.

Jn 6. Ristimärgid Nõo kiriku kooriruumi välisseinal.

Photo / Foto: Martin Malve

⁹ TÜ 2520: 19.



Fig. 7. View to the earthworks next to the southern side of the Pilstvere church.

Jn 7. Vaade Pilstvere kiriku lõunaküljel toimunud mullatöödele.

Photo / Foto: Martin Malve



Fig. 8. Finds from the Pilstvere churchyard: 1 – triangular padlock from the 16th – 17th century, 2 – key.

Jn 8. Pilstvere kirikaist leitud esemed: 1 – 16.–17. sajandist pärinev kolmnurkne tabalukk, 2 – võti.

(TÜ 2522: 4, 5.)

Photo / Foto: Martin Malve

individuals. Pathological analysis revealed only dental caries and dental calculus. In addition to the bones from the inhumation burials, also three bone fragments from cremation burials were discovered.

PÕLTSAMAA CHURCHYARD

The illegal soil work on the heritage protection area of the Põltsamaa fort and St Nicholas church unearthed the remains of four skeletons. It appeared that the trench had been dug into the intact burial layer on the south-western side of the church and also damaged the stone wall of the fort in the south-eastern part of the courtyard (Malve & Roog 2016).

National Heritage Board in 1998 (Valk 1999a; 1999b). Two disturbed graves were documented as well as a foundation of the stone wall of the churchyard; several burnt human bones, numerous commingled bones, coffin nails, brooches, fragments of spiral tubes, pendants, beads and coins were found (Valk 2000, 50–51).

In 2015, a layer of soil of ca. 20–30 cm was removed near the southern wall of the church in order to redesign the flower beds (Fig. 7). After the removal of the turf layer, a lot of human bones were revealed (Malve 2016b). A number of nails and bottle caps, but also some archaeologically valuable items were found. Investigating the disturbed cultural layer with metal detectors brought to the light a 16th – 17th-century triangular padlock (Konsap 1971, 96) with traces of heat on it and a key (Fig. 8) as well as three coins from the 17th – 19th centuries.¹⁰

Human remains

Altogether 50 human bones and fragments were collected.¹¹ The bones had been severely damaged due to various soil works (e.g. commingled by later burials and construction works). Many bone pieces were bleached, indicating that they had been lying on the ground for longer period. Skeletal parts belonged to both adults and subadults. Due to the heavy fragmentation of the osteological material, it was impossible to determine the minimal number of the

¹⁰ TÜ 2522: 1–5.

¹¹ After the osteological analysis all bones were reburied in the Pilstvere churchyard.

The old parish church of Põltsamaa, situated on the eastern bank of the River Põltsamaa was destroyed during the war between Poland and Sweden in 1600–1629 (Raam 1999, 107). The ruins were not rebuilt and a new church was erected on the walls of the Põltsamaa fort in 1632–1633, using the gate construction and round cannon tower as a basis (Alttoa 1995, 5). This church building suffered heavily during the Great Northern War in 1703 and was restored in the 1750s (Raam 1999, 108). Until recently there was only data about burials near the ruins of the old parish church (Kuurme 2011, 21; Malve & Kokamägi 2015) and no information existed about the cemetery at the new church. However, on the southern side of the church, a chapel with a crypt under it was located; it belonged to the family of the land-lord Heinrich Claus von Fick (1678–1750). The ruins of the chapel were demolished in 1958 to build a boiler house for the church (Kuurme 2011, 14). It is possible that the surroundings of the chapel were used as a burial ground.

There have been several earthworks around the church but none of them have been documented archaeologically. Already in the course of construction work of the boiler house in the 1950s there could have been bone findings. The fort courtyard has been more thoroughly archaeologically investigated (see Tvauri 2007, fig. 5), but mostly in the buildings of the fort. Excavations took place in front of the north-western entrance of the church in the 1970s with the aim to establish the architectural history of the church (*op. cit.*, fig. 5, area marked in red).

The trench of 2015 was dug between the south-eastern wall of the fort and the boiler house (Fig. 9). According to the bones collected from the removed soil and the bottom of the trench the digging had disturbed four *in situ* skeletons. It was possible to determine the original location of two burials by the profile of the trench. A skeleton of a young female (no. 1) was preserved in the south-western profile of the trench only by the bones of the left foot. She was buried in the depth of 1.25 m from the present-day ground level. The skeleton of a middle-aged male (no. 2) was traced in the bottom of the trench by the *in situ* lower legs; the skeleton lied 1.85 m below surface. Both burials had been placed in the grave on their backs in a stretched position; their heads had been directed to the west (220°). It was impossible to determine the original location of burials no. 3 and 4, as these were subadults whose relatively small skeletal remains were entirely unearthed. Artefacts related to definite burials were not



Fig. 9. Location of the burials between the south-eastern wall of the fort and the boiler house of the church in Põltsamaa.

Jn 9. Matuste asukoht Põltsamaa linnuse kagumüüri ja kiriku katlamaja vahel.

Photo / Foto: Martin Malve

found. The removed soil was scanned with a metal detector. A Polish silver coin¹² from the year 1836 and a musket bullet¹³ were collected, but they originate from a later period and are not connected to the burials. The disturbed soil also contained a single fragment of a ceramic vessel from the 16th – 17th centuries.¹⁴ Besides the skeletons two stray bones (a humerus and a fragment of the thoracic vertebra) that belong to adults were found, which do not suit with any of the skeletons. This indicates that the area may hide more burials. The age of the burial ground is hinted by the debris layer that covers the burials and contains lots of fragments of tiles from the 15th – 17th century.¹⁵ Since the debris layer is thicker near the church and goes thinner further, it may originate from the church building. It can be deducted that the burials took place on the site before the destruction of the church in 1703 or before its reconstruction in the 1750s. The burial ground may be related to the von Fick family chapel. It may have also been used for a short time during a war or an epidemic.

Skeletons

Altogether four individuals were distinguished in the osteological material¹⁶ (Table 2). The bones bore numerous fractures and damages caused by digging. It was possible to gather most of the bones from the three skeletons while the fourth skeleton was preserved very fragmentally. The right side of the cranium of the 6–10-year-old child (skeleton no. 3) was coloured lightly green due to copper corrosion. There could have been a grave good near the deceased, for example a copper coin or brooch.

Several pathologies were detected on teeth – dental caries, *ante mortem* lost teeth, alveolar reduction, periapical lesions and dental calculus. The teeth of skeletons nos. 1–3 were in bad condition, indicating food rich in carbohydrates. Schmorl's nodes found from the thoracic vertebrae of the adult male are a sign of heavy physical work in his younger life. Surprisingly, intervertebral herniations were detected also on thoracic vertebrae of a 16–18-year-old female that can be also caused by heavy physical stress.

Table 2. Sex, age and significant pathologies of the skeletons from Põltsamaa.

Tabel 2. Põltsamaalt leitud luustike sugu, vanus ja silmapaistvamad patoloogiad.

Compiled by / koostanud Martin Malve

Burial no. / Matus nr	Sex / Sugu	Age / Vanus	Pathologies / Patoloogiad
1	♀	16–18 y / a	Metopic suture still present; unfused arch of the atlas; Schmorl's nodes on the V–VIII thoracic vertebrae; medium dental calculus; dental caries; periapical lesions
2	♂	45+ y / a	Healed fracture of the mid part of the diaphysis of the left V metacarpals; osteoarthritis on elbow, wrist, hip and knee joints; ivory osteomas on frontal and parietal bone; Schmorl's node VI thoracic vertebra; compression fractures on X and XI thoracic vertebrae; dental calculus; remarkable alveolar reduction; dental caries; periapical lesions
3	?	6–10 y / a	Dental caries and dental calculus
4	?	0–4 (6) m / k	-

¹² TÜ 2534: 1.

¹³ TÜ 2534: 2.

¹⁴ Pers. comm. Andres Tvauri 02 May 2016; TÜ 2534: 3.

¹⁵ Pers. comm. Andres Tvauri 02 May 2016.

¹⁶ After the osteological analysis all human remains were reburied.

CONCLUSIONS

Archaeological rescue excavations in the churchyard of Nõo gave a lot of new information about the size and users of the burial ground. In Põltsamaa, a previously unknown burial place was discovered on a site of a historical chapel near the church. Investigations on the southern side of the Pilistvere church showed vividly that even a mixed cultural layer may present important information about the churchyard. The human remains collected from the churchyards are the most direct source for studying the health and lifestyle of the rural populations in the Middle Ages and Early Modern Times. A male cranium with a *peri mortem* sword wound from Nõo is definitely not a typical find and it provides us data about interpersonal violence outside the towns. Further archaeological investigations in the churchyards should include collecting all the finds including the ones found in the mixed cultural layer.

ACKNOWLEDGEMENTS

The research was supported by institutional research funding IUT20-7 of the Estonian Ministry of Education and Research. The author would like to thank Maarja Tammemägi, Juhani Kokamägi, Elis Tiidu, Freydis Ehrlich, Margot Laneman, Ants Liivak, Mari-Anne Liblik, Arthur Malve, Madli Oras, and Janika Viljat who took part in the fieldwork; Raido Roog, Toomas Tamla and Kati Salo for helpful comments and Anti Lillak for translation.

REFERENCES

- Allmäe, R. 1998.** Tääksi 14.–18. sajandi populatsiooni demograafiline analüüs ja kehapikkuse rekonstrueerimine. – Loodus, inimene ja tehnoloogia. Interdistsiplinaarseid uurimusi arheoloogias. Comp. by J. Peets. Ed. by V. Lang. *Muinasaja teadus*, 5. Tallinn, 163–187.
- Altoa, K. 1995.** Viljandi praostkonna kirikud. Ed. by J. Tammsalu. Viljandi.
- Altoa, K. 1999.** Nõo Laurentsiuse kirik. – Tartumaa, Jõgevamaa, Valgamaa, Võrumaa, Põlvamaa. Ed. by V. Raam. *Eesti Arhitektuur*, 4. Tallinn, 84–85.
- Brothwell, D. R. 1981.** Digging up Bones. New York.
- Brooks, S. & Suchey, J. M. 1990.** Skeletal age determination based on the os pubis: A comparison of the Acsádi-Nemeskéri and Suchey-Brooks methods. – *Human Evolution*, 5, 3, 227–238.
- Buikstra, J. E. & Ubelaker, D. H. (eds) 1994.** Standards for Data Collection from Human Skeletal Remains. *Arkansas Archeological Survey Research Series*, no. 44. Arkansas.
- Connell, B. & Miles, A. 2010.** The city Bunhill burial ground, Golden Lane, London. Excavations at South Islington schools, 2006. *MOLA archaeology studies series*, 21. London.
- Cowie, R., Bekvalac, J. & Kausmally, T. 2008.** Late 17th- to 19th-century burial and earlier occupation at All Saints, Chelsea Old Church, Royal Borough of Kensington and Chelsea. *MOLAS archaeology studies series*, 18. London.
- Faccia, K. J. & Williams, R. C. 2008.** Schmorl's nodes: clinical significance and implications for the bioarchaeological record. – *International Journal of Osteoarchaeology*, 18, 1, 24–44.
- Garmus, A. 1996.** Lithuanian Forensic Osteology. Vilnius.
- Garmus, A. & Jankauskas, R. 1993.** Methods of person's identification from the skeleton in Lithuania. – *Medicina Legalis Baltica*, 3–4, 5–23.
- Johanson, K. & Jonuks, T. 2015.** Superstition in the house of God? Some Estonian case studies of vernacular practices. – *Mirator*, 16: 1, 118–140.
- Konsap, V. 1971.** Dekoratiivne sepis Tallinna arhitektuuris XVI–XVIII sajandil. Tallinn.
- Kuurme, H. 2011.** Pildikesi Põltsamaa ajaloost. Praost-emeeritus Herbert Kuurme mälestusi ja tagasivaateid. Põltsamaa.
- Malve, M. 2016a.** Päästekaevamised Nõo Püha Laurentsiuse kirikaia 2015. a (reg nr 4256). Tartu. (*Manuscript in TÜAK.*)
- Malve, M. 2016b.** Aruanne arheoloogilistest uuringutest Pilistvere kirikaia 2015. a augustis (reg nr 14547). Tartu. (*Manuscript in TÜAK.*)
- Malve, M. & Kokamägi, J. 2015.** Archaeological excavations in the Põltsamaa old parish cemetery. – *AVE*, 2014, 175–182.
- Malve, M. & Roog, R. 2016.** Aruanne arheoloogilistest päästekaevamistest Põltsamaa Niguliste kiriku ja linnuse alal 2015. a sügisel. (*Manuscript in TÜAK.*)

- Malve et al. 2014a = Malve, M., Kadakas, V., Kiudsoo, M. & Tiidu, E. 2014.** Archaeological studies in the church and churchyard of Kose. – AVE, 2013, 119–134.
- Malve et al. 2014b = Malve, M., Roog, R. & Tiidu, E. 2014b.** Arheoloogilised päästekaevamised Kose kirikaias (reg. nr. 14) 11.–28. juunil 2013. aastal. Tartu. (*Manuscript in TÜAK.*)
- Manchester, K. 1983.** The Archaeology of Disease. Bradford.
- Ööbik, P., Kalm, A., Malve, M. & Toos, G. 2015.** Archaeological studies at the site of the new Narva border station. – AVE, 2015, 175–192.
- Ortner, D. J. & Putschar, W. G. 1985.** Identification of Pathological Conditions in Human Skeletal Remains. Washington.
- Raam, V. 1999.** Põltsamaa Nigula kirik. – Tartumaa, Jõgevamaa, Valgamaa, Võrumaa, Põlvamaa. Ed. by V. Raam. *Eesti Arhitektuur*, 4. Tallinn, 107–108.
- Roberts, C. & Manchester, K. 2012.** The Archaeology of Disease. Third Edition. Cornell.
- Schaefer, M., Black, S. & Scheuer, L. 2009.** Juvenile Osteology. A Laboratory and Field Manual. Amsterdam.
- Stirland, A. 2009.** Criminals and paupers: the graveyard of St Margaret Fyebrieggate in *combusto*, Norwich. *East Anglian Archaeology*, 129. Norfolk.
- Todd, T. W. 1920.** Age changes in the pubic bone. I: The male white pubis. – American Journal of Physical Anthropology, 3, 3, 285–334.
- Todd, T. W. 1921.** Age changes in the pubic bone. III: The pubis of the white female. IV: The pubis of the female white-negro hybrid. – American Journal of Physical Anthropology, 4, 1, 1–70.
- Trotter, M. 1970.** Estimation of stature from intact long bones. – Personal Identification in Mass Disasters. Washington, 71–83.
- Tvauri, A. 1999.** Rescue excavations on Kaubi village cemetery and supervision in the churchyards of Kambja and Nõo. – AVE, 1998, 133–140.
- Tvauri, A. 2007.** Arheoloogilised leiud Põltsamaa linnusest. – Põltsamaa lossi sees ja ümber. Põltsamaa Muuseumi Toimetised. Põltsamaa, 85–116.
- Ubelaker, D. H. 1989.** Human Skeletal Remains. Excavation, Analysis, Interpretation. *Manuals of Archaeology*, 2. Second edition. Washington.
- Valk, H. 1999a.** Arheoloogilisest inspeksioonist Pilistverre 24. mail 1999. Tartu. (*Manuscript in TÜAK.*)
- Valk, H. 1999b.** Aruanne arheoloogilistest uurimistöödest Pilistvere kirikaias 1999. a. juulis. Tartu. (*Manuscript in TÜAK.*)
- Valk, H. 2000.** Archaeological investigations in Late-Prehistoric-Early Medieval Viljandi and in Pilistvere churchyard. – AVE, 1999, 39–53.
- Valk, H., Ratas, J. & Laul, S. 2014.** Siksälä kalme, II. Matuste ja leidude kataloog. Tartu.

VÄLITÖÖD NÕO, PILISTVERE JA PÕLTSAMAA KESK- JA VARAUUSAEGSETES KIRIKAEDADES

Martin Malve

Viimastel aastatel on maakirikute renoveerimise ja kaasajastamise tõttu nende juures toimunud üha rohkem arheoloogilisi välitöid. Kohalikud kogudused on väga aktiivsed kasutamaks selle jaoks erinevaid toetusi ja annetusi. Enamasti on uuringud ajendatud kommunikatsiooniliinide paigaldamisest, mis ulatuvad kirikaedades puutumata kultuurikihini.

2015. a välitööd olid esimesed suuremad arheoloogilised uuringud **Nõo kirikaia**s. Kirikusse veeti vee- ja kanalisatsioonitrass, mille jaoks rajati viis väiksemat auku ning kaevand (jn 1).

Uuringute käigus avastati 19 *in situ* matust (tabel 1), millest puhastati välja 18. Lisaks võeti üles arvukalt lõhutud matustest pärinevaid luid. Surnud olid sängitatud selili-siruli asendis, peaga läände. Enamik surnuid oli sängitatud vahemikku 0,7–1,1 m maapinnast. Väikese hauasügavuse tõttu oli enamik luustikke pealematmistega lõhutud (jn 3). Kirstu kõdupuitu tuvastati vaid ühe matuse juures (luustik nr 13), kolme luustiku (nr 4, 16 ja 17) puhul viitas kirstu olemasolule kehaasend ja luude paiknemine. Matmistihedus oli väike, surnud olid tavaliselt ühes-kahes kihis, üksikul juhul ka kuni neljas kihis. Välitöödel selgus, et kalmistu ulatub kirikaia ümbritsetud alalt oluliselt väljapoole (jn 2).

Osteoloogilise analüüsiga tuvastati 14 täiskasvanut ja viis alaealist. Luustikel leiti vanusega kaasnevaid haigusi (tabel 1): jäsemeliigeste kulumist (osteoartroos) ja lülisamba degenereerumist (kaelalülide osteokondroos, spondüloartroos ja spondüloos). Enim esines osteoloogilises aineses hammastega seotud patoloogiaid (kaaries, hambakivi, alveolaarkarte taandumine, periapikaalsed hambapõletikud). Kahe täiskasvanud mehe sääre- ja pindluudel tuvastati periostiiti e luuümbrise põletikku. Schmorli sõlmi e lülivahekettaga leiti nelja täiskasvanu rinna- ja nimmeliidel. Kahe luustiku kolju otsmiku- ja kiiruluudel avastati mitu punktosteoomi. Lisaks eespool nimetatud tootimise ja igapäevaeluga seotud patoloogiatele tuvastati ühe 40-aastaselt täiskasvanud mehel kuklaosas terariista u 7,6 cm pikkune lõikejalg (jn 4). Lisaks oli mehel vasaku rangluu külgmises osas paranenud luumurd ning selgroo liigesepindadel osteofüüdid ja lüliliikahadel Schmorli sõlmed, mis annavad märku nii kõrgest vanusest kui ka suurest füüsilisest koormusest. Lõikejalg oli sama tooni ülejäänud koljuga, millest võib järeldada, et tegemist on surmaaegse vigastusega. Enamasti esinevad silmast-silma võitluses saadud terariistahaavad otsmiku- ja kiiruluudel. Antud juhul viitab haava asukoht kuklas rünnakule selja tagant. Maakirikaedades on seni taoliste vigastustega luid leitud vaid Koselt, kus avastati kaks luustikku, millel olid surmavad haavad koljudel. Enamike maakirikaedades leitud inimluude osteoloogiline analüüs on alles ees.

Välitöödel koguti mitmeid esemeid nii luustike juurest kui ka matusekihist. Segatud ladestustest võeti üles keskaegne vitssõlg (jn 5: 1). Ülematmistega lõhutud matustest pärinevad kindlasti ka helmed (jn 5: 2–3), pannal ja vitssõrmus. Ühe naiseluustiku (luustik nr 10) juurest leiti panusena nuga, mis asus tema vasaku puusa juures, teisest naisematusest (luustik nr 12a) aga 14.–15. sajandi spiraalsõrmus ja hoburaudsõlg (jn 5: 4–5). Täiskasvanud mehe vasaku niudelu pealt puhastati välja metallist võõrõngas (luustik nr 13). Luustik 14 mõlema rangluu rinnakmise osa kohalt (jn 5: 6–7) ja rindkere vasaku poole X roide juurest (jn 5: 8) leiti spiraalitorude katkeid. Lisaks matustega seotud esemetele leiti arvukalt kiriku aknaklaasi kilde ja üks tinaraami katke. Välitöödel avastati kiriku kooriruumi välisküljelt kaks krohvi alt paljandunud ristimärki (jn 6).

Pilistvere Andrease kiriku lõunaküljel asunud nartsissipeenarde uuendamisel eemaldati u 20–30 cm pinnast (jn 7), millest leiti arvukalt inimluid ja üksikuid arheoloogiliselt huvipakkuvaid esemeid. Metallotsijatega lõhutud kultuurikihti üle vaadates avastati 16.–17. sajandist pärinev tuld saanud kolmnurkne tabalukk ja võti (jn 8) ning kolm münti 17.–19. sajandist. Kokku leiti 50 inimluud ja selle fragmenti. Luud olid mitmete mullatööde käigus saanud tugevasti kannatada. Kõik luud olid ülematmistest või varasemate kaevetöödega segatud. Skeletiosi oli nii täiskasvanutel kui ka alaealistel, kuna luud oli väga fragmenteerunud, siis vähimat indiviidide arvu ei olnud võimalik määrata. Patoloogiatest õnnestus tuvastada kaariest ja hambakivi. Lisaks laibamatusest pärinevatele luudele leiti kolm põletusmatustest pärinevat inimluu fragmenti.

Ebaseaduslike kaevetöödega tulid **Põltsamaa linnuse ja kiriku** kaitsealas välja nelja luustiku jäänused. Trassi ehitusel oli kiriku edelaküljel läbi kaevatud puutumata matustest ning linnuse hoovi kaguosas müürist. Seni teadaolevalt kasutati surnuaiana vaid vana Põltsamaa kihelkonnakiriku varemete ümbrust, mis hävis Poola-Rootsi sõdades (1600–1629), andmed uue kiriku juurde matmise kohta puudusid. Küll aga oli teada, et kiriku lõunaküljel asus mõisnik Heinrich Claus von Ficki perekonna kabel koos selle all olnud hauakambriga, mis lammutati 1958. a seoses uue katlamaja rajamisega. Põltsamaa kiriku juures on tehtud mitmeid mullatöid, kuid varem pole neist ühtegi arheoloogiliselt dokumenteeritud.

Trass oli kaevatud linnuse kagumüüri ja kiriku katlamaja vahele (jn 9). Kahe luustiku (luustikud nr 1, 2) puhul oli *in situ* jäänud luude abil võimalik tuvastada nende algne asukoht. Surnud oli sängitatud 1,25–1,85 m sügavusele maapinnast. Mõlemad surnud olid maetud selili-siruli asendis peaga läände. Matuste nr 3 ja 4 algset asukohta ei olnud võimalik kindlaks teha. Haudade kohal asunud ehitus/lammutusrusu kihi põhjal, võib järeldada, et matused pärinevad arvatavasti 17. sajandi lõpust või 18. sajandi I poolest. Tegemist võib olla ka ajutise matmispaigaga, mida on kasutatud näiteks sõja või mingi suurema haiguspuhangu ajal või on see hoopis seotud Ficki perekonna kabeliga.

Kokku tuvastati lõhutud luude hulgast neli indiviidi (tabel 2). Esimese kolme luustiku puhul õnnestus pinnasest välja korjata enamik luid, vaid neljanda luustiku puhul jäi suur osa leidmata. Hammastel tuvastati kaariest, eluajal väljalangenud hambaid, alveolaarkaarte taandumist, periapikaalseid hambapõletikke ja hambakivi. Kolme esimese indiviidi hambad olid halvas seisus, mis viitab süsivesikuterikkale toidule. Füüsilisele stressile osundasid mehe rinnalülide kehael tuvastatud Schmorli sõlmed. Lülivaheketaste songasid esines ka 16–18-aastase neiu rinnalülidel, mis võib viidata väga suurele koormusele juba varases eas.

Arheoloogilised päästeuuringud Nõo kirikaia andsid teavet kalmistu suuruse ja kasutajaskonna kohta. Uuringud Pilistvere kiriku lõunaküljel näitasid, et isegi segatud kihi läbivaatamisel võib saada mitmekülgset teavet kirikaia kohta. Põltsamaa kiriku juures toimunud kaevetöödel avastati varem teadmata matmispaik kiriku kunagise kabeli juures. Kirikaedadest kogutud inimluud on kõige otsemaks ja paremaks vahendiks hindamiseks maaelanike tervist ning elustiili kesk- ja varauusajal. Nõo kirikaiaist leitud fataalse mõõgahaavaga mehe kolju on erandlik leid, seni on valdav enamik surmavate vigastuste jälgedega luustikke leitud linna-kalmistutelt. Kindlasti tuleb järgnevatel kirikaedadega seotud arheoloogilistel väljakaevamistel üles võtta ja hoolikalt läbi uurida ka lõhutud kalmistu kultuurkihi leiud.