

# 2<sup>nd</sup> Baltic Conference of Radiology

24-25 Oct, 2008  
Tartu, Estonia



UNIVERSITY OF TARTU



Estonian Society of  
Radiology

Latvian Association of Radiology  
Lithuanian Radiologists' Association

**EESTI ARST**

Eesti Arst 2008; 87(10 Lisa):693–728

## Sponsors:

### Main sponsor:

Siemens **SIEMENS**

### Gold sponsors:

Agfa **AGFA** 

Overall Medical OÜ **OVERALL MEDICAL** 

Bayer-Schering-Pharma  **Bayer HealthCare**

Hansa Medical  **Hansa Medical**

Medicum Tehnika  **TOSHIBA**

Meditsiinigrupp

### Silver sponsors:

GE Healthcare  GE imagination at work

One Med **ONEMED**

Semetron

# Programme

## FRIDAY 24<sup>TH</sup> OCTOBER

8.00–17.00 **REGISTRATION**

9.00 **OPENING**

9.30–12.00 **NEURORADIOLOGY**

Chairman Prof. Gaida Krumina,  
Riga, Latvia

9.30 **Imaging of tumours**

D. Auer, Nottingham,  
United Kingdom

10.15 **Advances in the treatment and  
imaging of glial tumours**

G. Krumina, Riga, Latvia

10.55 **Role of magnetic resonance  
diffusion and ADC values in  
brain tumour diagnostics**

S. Dzelzite, Riga, Latvia

11.05 **MR spectroscopy – technical  
basics and clinical highlights**

I. Björkman-Burtscher, Lund,  
Sweden

11.50 **First experience and results of  
fetal brain MRI of 12 patients.**

S. Dzelzite, J. Purvina, D. Matule,  
D. Ezerina, Riga, Latvia

9.30–12.00 **NUCLEAR MEDICINE/PET**

Chairman Dr. Sergei Nazarenko,  
Tallinn, Estonia

9.30 **PET imaging in lymphomas**

G.A. Wisemann, Mayo, Minnesota

10.15 **First radio-immunotherapy with  
Zevalin in Estonia**

S. Nazarenko Tallinn, Estonia

10.45 **PET tracers beyond FDG**

G.A. Wisemann, Mayo, Minnesota

11.30 **Nuclear diagnostic pathology of  
parathyroid glands**

I. Vevere, Riga, Latvia

12.00–13.00 **Lunch**

13.00–15.30 **CEREBRAL VASCULAR IMAGING  
AND INTERVENTIONS**

Chairman Dr. Tommy Andersson,  
Stockholm, Sweden

13.00 **Imaging of acute stroke: CT and  
MRT studies**

H. Almqvist, Stockholm, Sweden

13.45 **Endovascular stroke  
management**

K. Kupcs, Riga, Latvia

14.00 **Stroke management;  
endovascular stroke  
management**

T. Andersson, Stockholm,  
Sweden

14.45 **Intracranial aneurysms in  
children and endovascular  
treatment**

K. Kupcs, Riga, Latvia

15.00 **Vertigo and tinnitus –  
neuroradiological management**

S. Dzelzite, Riga, Latvia

- 13.00–15.30 **ABDOMINAL IMAGING/  
TRANSPLANTATIONS**  
Chairman Prof. Algidas  
Basevicius, Kaunas, Lithuania
- 13.00 **Pancreatic transplant imaging**  
L. Pöder, San Fransisco, USA
- 13.45 **Imaging in liver transplantation**  
A. E. Tamosiunas, Vilnius,  
Lithuania
- 14.30 **Leiomyosarcoma of inferior  
vena cava**  
E. Bieliuniene, G. Kavaliauskiene,  
D. Mitraite, E. Jonaitiene,  
A. Basevicius, V. Krasauskas,  
D. Pranyš, S. Lukosevicius,  
E.B. Juodzbaliene, Kaunas,  
Lithuania
- 14.45 **Ultrasonography in diagnosis of  
renal tuberculosis**  
M. Radzina, E. Kadakovska,  
I. Simanovica, Latvia
- 15.00 **Ultravist® - When balance  
matters: a comparative review  
of nonionic monomers versus  
the isotonic nonionic dimer  
iodixanol**  
Company presentation:  
Dr. Hans Peter Niendorf,  
Diagnostic Imaging Bayer  
Schering Pharma AG
- 15.30–16.00 **Coffee**
- 16.00–18.30 **PAEDIATRIC IMAGING**  
Chairman Prof. Olof Flodmark,  
Stockholm, Sweden, and Assoc.  
Prof. Pilvi Ilves, Tartu, Estonia
- 16.00 **Development of brain damage in  
infants**  
O. Flodmark, Stockholm, Sweden
- 17.00 **Changes in cerebral and  
visceral blood flow velocities  
in asphyxiated term infants  
with hypoxic ischaemic  
encephalopathy**  
P. Ilves, M. Lintrop, I. Talvik,  
K. Muug, L. Maipuu, T. Metsvaht,  
Tartu, Estonia
- 17.30 **Reorganization of the  
developing human brain after  
early lesions (including TMS  
and fiber tracking)**  
M. Staudt, Tübingen, Germany
- 16.00–18.30 **ABDOMINAL IMAGING/ACUTE  
PATHOLOGY**  
Chairman Assoc. Prof. Jurate  
Dementavicienė, Vilnius,  
Lithuania, and Assist. Prof.  
Antonio Westphalen, USA
- 16.00 **Pearls and pitfalls of abdominal  
CT**  
A. Westphalen, San Francisco,  
USA
- 16.45 **Value of multi-detector  
computed tomographic (MDCT)  
angiography in diagnosis of  
gastrointestinal (GI) bleeding**  
G. Kavaliauskiene, A. Basevicius,  
Kaunas, Lithuania
- 17.15 **Radiological evaluation of  
early complications of acute  
pancreatitis**  
A. Samuilis, A. Rutkauskaite,  
J. Dementaviciene, A. Sileikis,  
Vilnius, Lithuania
- 17.45 **Acute abdomen in children**  
J. G. Blickman, Nijmegen,  
Netherlands
- 19.30 **Get together party**

**SATURDAY 25<sup>TH</sup> OCTOBER**

- 8.30–11.00 **PELVIC IMAGING**  
Chairman. Assist. Prof. Liina Pöder, San Francisco, USA, and Dr. Karin Asser, Tartu, Estonia
- 8.30 **Adnexal pathology: US/MRI correlation**  
L. Pöder, San Francisco, USA
- 9.15 **Top 10 gynecologic indications for MRI**  
A. Westphalen, San Francisco, USA
- 10.00 **Uterine pathology: cervical and endometrial cancer**  
L. Pöder, San Francisco, USA
- 10.45 **PACS – future perspectives**  
Company presentation:  
Mek Nielsen, Agfa
- 8.30–11.00 **FUNCTIONAL MAGNETIC RESONANCE IMAGING AND DIFFUSION TENSOR IMAGING**  
Chairman Prof. Hannu Aronen, Turku, Finland
- 8.30 **Diffusion tensor imaging, technical aspects**  
P. Morgan, Nottingham, United Kingdom
- 9.10 **Diffusion and functional MRI, clinical indications**  
C. Ojango, Nottingham, United Kingdom/Estonia
- 9.50 **Cerebral fMRI**  
H. Aronen, Turku, Finland
- 10.20 **fMRI in paediatric neurorehabilitation**  
M. Staudt, Tübingen, Germany
- 11.00–11.30 **Coffee**
- POSTER SESSION**  
Chairman: Prof emer. Jüri Kaude, Assoc. Prof. Pilvi Ilves
- 11.30–13.30 **MUSCULOSKELETAL**  
Chairman: Assoc. Prof. Ardis Platkajis, Riga, Latvia
- 11.30 **Radiological diagnostic of osteoporosis and complications**  
A. Platkajis, Riga, Latvia
- 12.00 **Radiological diagnosis of early arthritis**  
L. Rutkauskiene, A. Venalis, J. Petronyte, Vilnius, Lithuania
- 12.15 **Risk factors of hip dislocation after primary total hip replacement (THR): clinical and radiological analysis**  
P. Likums, G. Krumina, P. Studers, Riga, Latvia
- 12.30 **Sports imaging**  
I. Boric, Croatia
- 13.00 **Image quality in digital images**  
Company presentation:  
Walter Streng. Carestream Health Inc. in cooperation with Overall Medical OÜ
- 11.30–13.30 **RADIATION PROTECTION**  
Chairman Dr. Mare Lintrop, Tartu, Estonia
- 11.30 **Radiation dose and optimization in paediatric CT**  
M. Kortnesniemi, Helsinki, Finland
- 12.10 **Radiation protection of the patient and personnel from medical exposure. New European directives**  
G. Bartal, Kfar-Saba Hospital, Israel
- 12.30 **Radiation dose and image quality assessment in CT**  
M. Kortnesniemi, Helsinki, Finland
- 13.00 **Dynamic Volume Cardio CT**  
Company presentation:  
Roy Irwan, Toshiba
- 13.30–14.30 **Lunch**

14.30–17.00 **CARDIAC IMAGING**

Chairman Assoc Prof. A. E. Tamosiunas, Vilnius, Lithuania

14.30 **MRI in non-ischaeamic acquired heart disease**

K. Ordovas, California, USA

15.15 **Evaluative function of cardiac MDCT of the right ventricle**

M. Mataciunas, D. Zakarkaitė, A. E. Tamosiunas, N. Valeviciene, Vilnius, Lithuania

15.30 **Cardiac MRT in children**

K. Lauerma, Helsinki, Finland

16.15 **Coronary CTA: a review of the anatomy and variants**

K. Ordovas, California, USA

**the oncological patient**

G. Bartal, Kfar-Saba Hospital, Israel

15.00 **Seamless integration of patient electronic health data**

P. Ross, Tallinn, Estonia

15.30 **Golden rules for management an imaging department**

S. Nazarenko, Tallinn, Estonia

16.00 **New trends of management in radiology**

M. Epermane, Latvia

16.30 **Estonia-PACS – an integral part of the national e-Health Programme**

M. Ulst, A. Aavik, A. Paats, R. Käpp, Tartu, Estonia

14.30 – 17.00 **MEDICAL INFORMATICS AND MANAGEMENT IN RADIOLOGY**

Chairman Dr. Mara Epermane, Latvia and Dr. Margus Ulst, Tartu, Estonia

14.30 **The role of the modern imaging specialist (radiologist) in the diagnosis and management of**

17.00–17.15 **Closing ceremony**

**Friday 24<sup>th</sup> October**

**Struve Hall**

Opening 9.00–9.30  
Neuroradiology 9.30–12.00  
Lunch 12.00–13.00  
Cerebral vascular imaging and interventions 13.00–15.30  
Coffee 15.30–16.00  
Paediatric imaging 16.00–18.30  
Get together party 19.30

**Baer Hall**

Nuclear medicine 9.30–12.00  
Lunch 12.00–13.00  
Abdomen/ transplantations 13.00–15.00  
Company: Bayer Schering Pharma AG 15.00–15.30  
Coffee 15.30–16.00  
Abdomen: acute pathology 16.00–18.30

**Saturday 25<sup>th</sup> October**


**Struve Hall**

Pelvic imaging of 8.30–10.45  
Company: Agfa 10.45–11.00  
Coffee 11.00–11.30, Poster session  
Musculoskeletal 11.30–13.30  
Lunch 13.30–14.30  
Management in radiology 14.30–17.00  
Closing ceremony 17.00–17.15

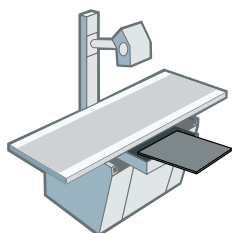
**Baer Hall**

fMRI 8.30–11.00  
Coffee 11.00–11.30, Poster session  
Radioprotection 11.30–13.00  
Company: Toshiba 13.00–13.30  
Lunch 13.30–14.30  
Cardiac imaging 14.30–17.00

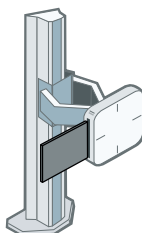
# KASUTA



**SIIN**



**SIIN**



**SIIN**



# VALMIS!

## TÄISDIGITAALNE RÖNTGENI LAHENDUS



TUTVUSTADES MAAILMA ESIMEST JUHTMEVABA DIGITAALSET DETEKTORIT, MIS ON KASSETI SUURUSEGA NING SOBIB KENASTI TEIE OLEMASOLEVATESSE SEADMETESSE. EI MINGEID JUHTMEID. EI MINGIT SEGADUST. **GENIAALSELT LIHTNE.**

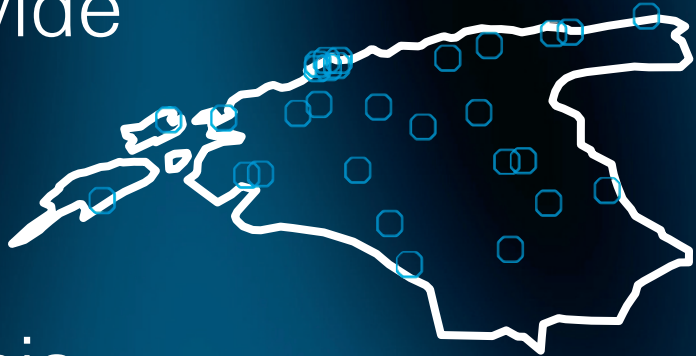
DRX-1 on maailma esimene juhtmevaba digitaalne detektor mille mõõtmed on samad kui 35cm x 43cm kassetil. Detektori paigaldamiseks pole vaja olemasolevaid seadmeid modifitseerida. Detektori lisamine muudab kabineti tööprotsessi sujuvamaks ning teie röntgeni lahenduse täisdigitaalseks.

Vaata lähemalt [www.overallmedical.ee](http://www.overallmedical.ee)

OVERALL  
MEDICAL

Carestream   
HEALTH

The first  
and only  
nationwide  
PACS  
in Estonia



## Eesti Tervishoiu Pildipank

### **Digitaalse meditsiiniinfo arhiveerimine**

Radioloogilised uuringud | EKG | Uuringuvastused

### **Veebipõhine ligipääs perearstidele**

### **Diagnostiliste tööjaamade tarkvaralahenduste müük ja rentimine**

Radioloogidele | Mammogrammide hindamiseks  
Ortopeedidele, sh. proteeside planeerimiseks  
Kardioloogidele

### **Foundation of Estonian PACS**

Estonian PACS was founded by Tartu University Hospital and North-Estonian Medical Centre in 2006 in order to archive medial images from all over Estonia. Today nationwide PACS is archiving 86% of all images produced by Estonian healthcare providers.

We are offering central archiving solutions, a web solution for GPs, a special software rental solution for radiologists, orthopaedists, mammologists and cardiologists.



## 2<sup>nd</sup> Baltic Congress of Radiology in Tartu, October 24–25 2008

---

**Jüri Kaude** – Prof. emer. of Radiology,  
University of Florida

---

The abstracts or scientific papers presented at the 2<sup>nd</sup> Baltic Congress of Radiology in Tartu are published in the current issue of *Eesti Arst*. The first Baltic Congress of Radiology was held in Kaunas in 2006. However, Baltic radiologists have convened previously twice, at the radiology-oncology meetings in 1994 in Tallinn, and in 1998 in Riga.

The summaries of the reports presented at the congress this year provide an overview of the present state of diagnostic imaging in the Baltic States. I have observed the development of radiology in Estonia since 1992, and I believe that the situation in Latvia and Lithuania has been comparable to that in my native country. Sixteen years ago, the available equipment of diagnostic radiology was about 40–50 years behind the technology used in medical institutions in the Western world. The younger radiologists whom I met were pushing hard towards acquiring up-to-date equipment and were eager to gain the knowledge to utilize it.

Over the years, and with the help of governmental public health institutions, such as health insurance agencies and hospitals, which all realized the importance of radiology in health care, this seemingly impossible task was accomplished. At the same time, training in radiology as a speciality of medicine was reorganized and brought to the level of present standards. During these developmental years Baltic radiologists have

found time for research activities as shown by the abstracts which are published in the present issue of *Eesti Arst*.

Certainly, much is still to be done and the gates of science are always open for new discoveries and for increasing the knowledge hitherto acquired. To achieve this, it is important to stimulate interest in radiology among medical students and young physicians, to further improve training programmes in radiology and to promote research activities. This is the task for teaching institutions and universities. It is of utmost importance that there is an independent radiology department in every medical school, chaired by a clinically competent and academically oriented radiologist. It is obstructive for patient care and development of diagnostic imaging to include radiology as a division of another department, or divide its functions between several other departments in a medical school.

The present Baltic Congress of Radiology is still mainly at the instructional level as is evident by the fact that roughly half of the 40 or 50 papers were presented by invited speakers. The international exchange of knowledge and experience is, of course, very important, and every congress has a certain „teaching-learning“ character, but let us hope that at the next congress, many more instructional courses or lectures will be conducted by Baltic radiologists.

In summary, much has been achieved but there is always room for improvement. Personally, I am very optimistic about the future development of radiology in the Baltic States.

## Activities of the Estonian Society of Radiology

**Peeter Ross** – President of the Estonian Society of Radiology

The aim of the Estonian Society of Radiology (ESR) is to promote radiology in Estonia, defend occupational interests of radiology professionals, improve speciality-related knowledge and develop the social activities. Being a professional organization it acts also as a trade union for the radiology field employees. This is mainly because of the small number of radiologists in Estonia that stimulates the organization to actively act in all radiology related fields. The main part of ESR members are radiologists but one can find there nuclear medicine specialists, biomedical engineers and radiology technicians. The society accepts only personal membership. A member can not be a legal entity. The history of the ESR dates back to the year 1992 and currently there are approximately 180 active members.

ESR is focusing on the interests of professionals in radiology. The activities of the society are carried out at the request of its members. ESR aims to reflect the needs of all radiology field professionals irrespective of the size of their department or geographical location. This is one of the main reasons why the events of the society are usually very well attended.

ESR is directed by the five-member management board – president, vice president and three members of the board. The board is elected for three years and the president can not hold the position for more than two

consecutive periods. Besides the board there is a Development Council with about 20 members who are elected also for a three-year period. The Development Council is an advisory body for the board, the main objective of which is to analyse the problems essential from the view of development of radiology and to make proposals for implementation on this basis both to the management board as well as to the general meeting. It has become a rule that it gathers once a year to analyse current radiology topics and draw up a yearly plan for ESR activities.

The main areas of the ESR activities are organization of continuous medical education for radiologists and radiology related professionals, cooperation with Tartu University Hospital to conduct radiology residency, participation in the development and execution of health care policy and of radiation- safety policy, creation of acceptable working conditions, organizing of social events for the members, certification of radiologists and foreign affairs. Below I would like to analyze all these topics more thoroughly.

During the last 15 years ESR has been the leading force in organizing radiology seminars, workshops and conferences in Estonia. The educational events are organized for different target groups. The most frequent event is so called *Wednesday seminars*. This block of seminars is meant for radiologists and is organized every second week both in Tallinn and Tartu during the educational season from September to May. It consists of two presentations: one

is about an actual topic in radiology and the other is a clinical case. At the end of the season the best presentation is selected and the speaker receives an award. This is also good opportunity for residents to practise presentation. Every resident has to make at least one presentation during the residency curriculum.

Besides the regular seminars there are at least two country-wide meetings for the ESR members. One of them is dedicated to administrative issues, the other to hot topics in radiology. During the last years multidisciplinary meetings have gained much popularity. This is an event where the radiology society meets one of the other speciality societies. The meeting covers presentations of both speciality and attempts to find common understanding in the overlapping areas. The latest examples of these kind of seminars are radiology-orthopaedic and urology seminars. Participation in any of the above mentioned seminars is taken into account at the ESR radiologists' certification.

Concern about the training of new generation of radiologists has been always one of the driving forces in ESR activities. During the early years of training radiology residents ESR played the leading role in the development of the curriculum and in the arrangement of training facilities. Now more and more responsibility is taken over by the University of Tartu. Nevertheless, the residency training programme is still developed in good cooperation with University, ESR and main hospitals in Estonia. Altogether 5–8 residents complete the residency programme annually. To follow the European curriculum, ESR is currently translating European Training Charter for Clinical Radiology into the Estonian language.

There is a tendency that some of the graduated radiologists start their radiologists' career in Finland or other Scandinavian countries rather than in Estonia. It is a good opportunity for young radiologists to gain experience from abroad, however, from the

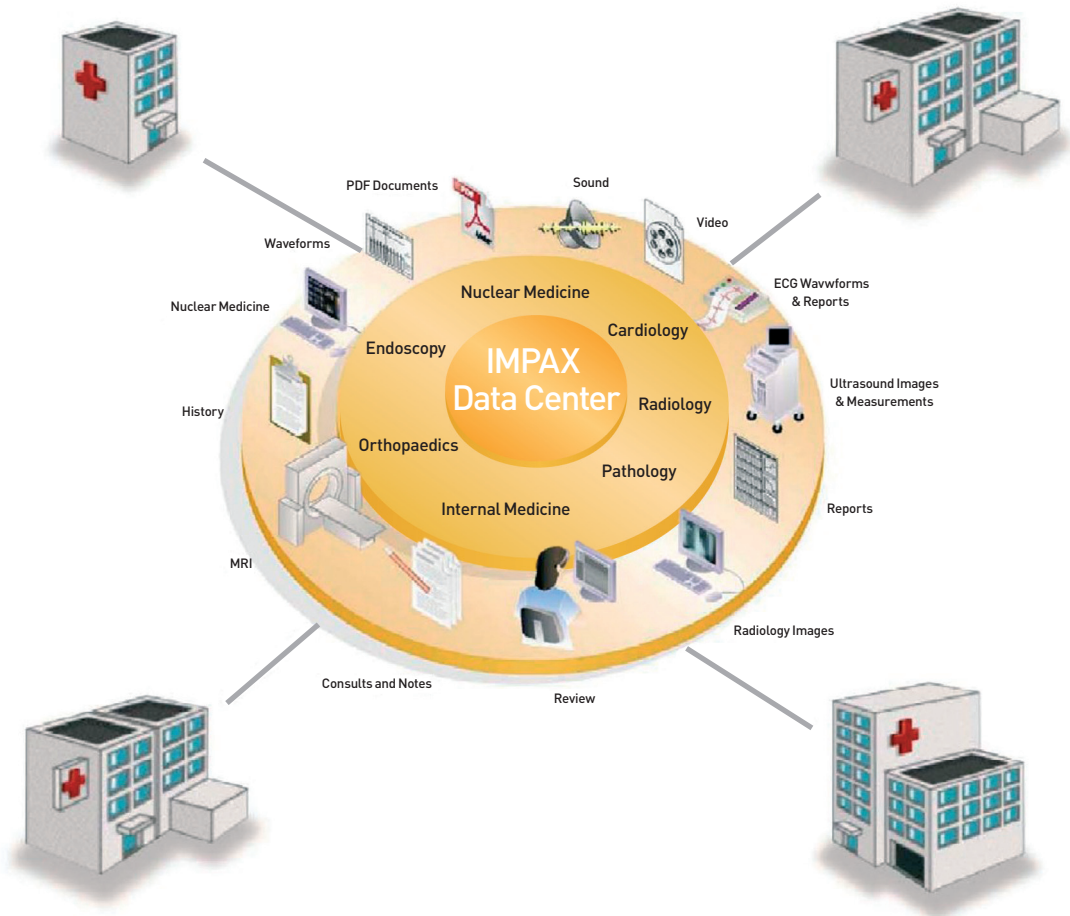
point of view of Estonian radiology it would be the worrying trend in case that number will increase or radiologists will stay abroad for years. In this way Estonia is a kind of sponsor for Scandinavian countries to prepare radiologists for them. This is still an ongoing trend even though the quality of equipment and salary conditions are improving rapidly in Estonia. This trend leads to the most challenging area of ESR activity – creation of acceptable working conditions for radiology related professionals. Improvement of working conditions involves a complex of actions. The main fields there are description of the quality criteria of the radiology examinations and procedures and elaboration of proper working conditions to ensure patient's and radiology field professionals' safety. ESR has been involved in development of Radiation Act and other related legal documents. These activities form the basis of the ESR demands in negotiations for the proper reimbursement prices for radiology examinations with the Estonian Health Insurance Fund and the Ministry of Social Affairs. Once the main part of the radiology examinations are reimbursed on the fee-for-service principle the balanced price serves as the basis for wages in the radiology field and for purchasing of new equipment.

Concerning the equipment used in radiology, the policy of ESR is to support usage of the latest high quality technology. The aim is to promote technology which helps to solve the patient's clinical problem in the most effective way, at the same time keeping radiation as low as possible. For instance, Picture Archiving and Communication System (PACS) with integration of Hospital Information System is a very powerful tool to obtain a holistic view of the patient's clinical problem and to include all imaging tests in diagnostic process. ESR in cooperation with Tartu University Hospital and other main hospitals in Estonia were the founders of the Estonian nation-wide PACS which is now completely functioning since 2006.

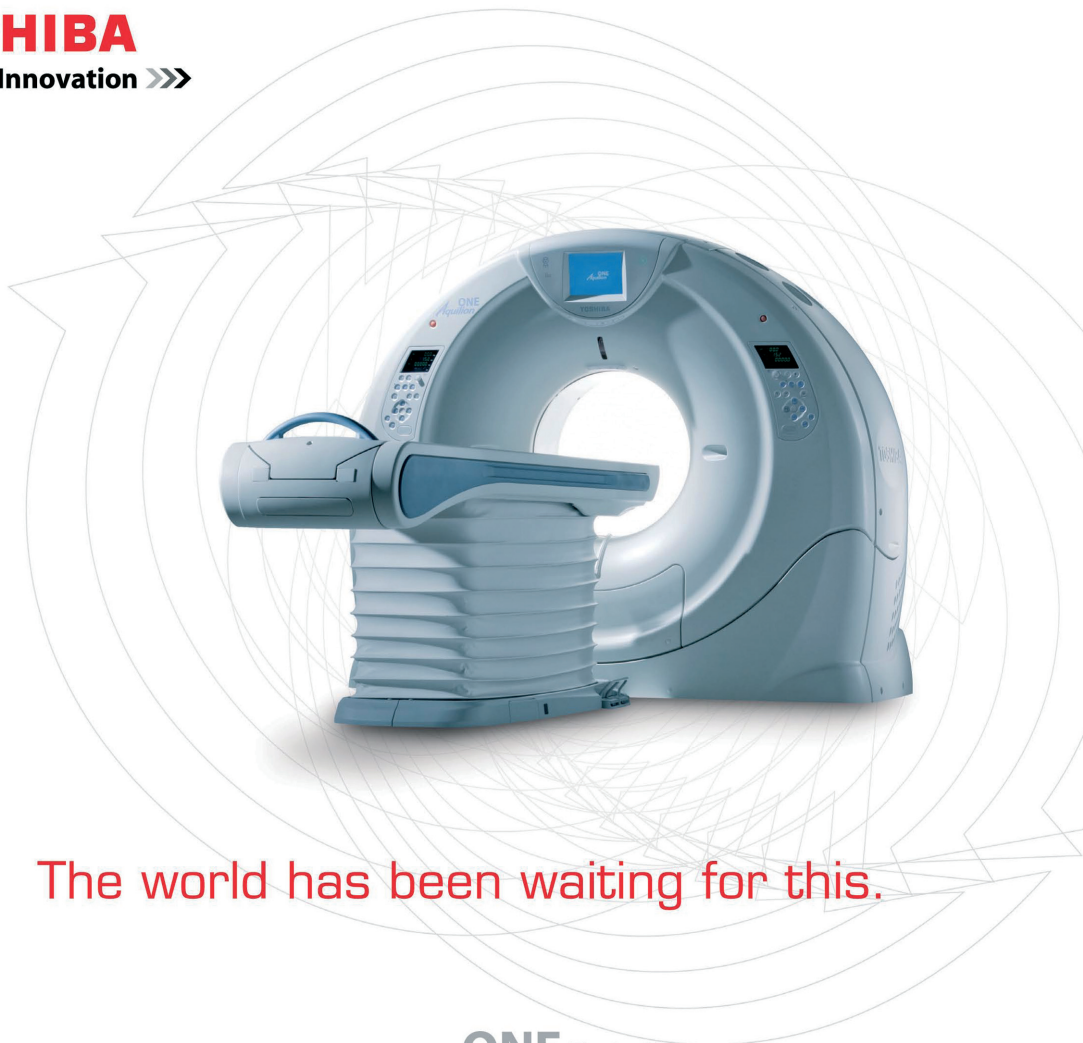Certification and re-certification of radiologists are conducted by the ESR certification board which is elected by the general meeting for three years. Certification is not a compulsory proving of radiologists competence but still most of radiologists are passing this procedure every fifth year. The aim of ESR is to use radiologists' certificate as an evidence of high professional skills in negotiating working conditions or reimbursement principles.

ESR is a member of European Society of Radiology, UEMS Radiology Section and

the International Society of Radiology. Very important part of foreign affairs is cooperation with neighbours – Latvian, Lithuanian and Finnish societies. It has become a rule that there are several events each year where lecturers or participants from neighbouring countries are taking part in the ESR meetings. The Baltic Conference of Radiology 2008 is excellent example of international cooperation between neighbours which aims at popularisation of radiology and exchanging good practice.



**TOSHIBA**  
Leading Innovation >>>



The world has been waiting for this.

**ONE** *Rotation*

**ONE** *Phase*

**ONE** *Volume*

**ONE** *Scan*

**ONE**  
*Aquilion*

**Medicum Tehnika OÜ**

Punane 61, Tallinn 13619

Phone (+372) 6 671 747, fax (+372) 6 671 748

# Latvian Association of Radiology

**Ardis Platkajis** – President of the Latvian Association of Radiology

The Latvian Association of Radiology was founded in 1926 as Radiologists Society of Riga. The chairman of the society was assistant professor E. Webers from Vienna. He became the first director of the Institute of Radiology at University of Latvia (5th in Europe) founded in 1929. In 1993 the Latvian Association of Roentgenology and Radiology was admitted in ECR and one year later in International Society of Radiology. The Association comprises 302 members (225 radiologists, 15 radiotherapists, 40 residents, 22 other specialists). The board and the president are elected for a four-year period. The certification committee is elected for a four-year period as well.

Main tasks of the association:

- to organize certification and recertification (credit point system since 2004);
- to cooperate with governmental authorities and state institutions in field of diagnostic and therapeutic radiology, including legislation, radiology safety, protection, education etc.;
- to cooperate with educational institutions;
- to organize local and international meetings;
- the meetings of the association are carried out 4 times yearly (refresher course reports, scientific reports and managerial problems are main structural basis of these meetings).

There are several associations of subspecialties:

- Association of Neuroradiology (founded in 1997, president Prof. G. Krumina)
- Association of Musculoskeletal Radiology (founded in 2002, president Dr. M. Epermane)
- Society of Ultrasound in Medicine and Biology (founded in 2003, president Dr. I. Sedleniece)
- Latvian Society of Radiographers (founded in 1996, president E. Rutka)
- Society of Radiotherapists of Latvia (founded in 2004, president Dr. O. Utehina)

Two educational institutions provide four-year residency programmes in radiology: Institute of Radiology of Riga Stradins University and Institute of Radiology of University of Latvia. Programmes based on ESR recommendations have state accreditation.

In the future:

- to work out, in cooperation with government institutions, a National PACS system project;
- to replace conventional radiological systems by digital systems;
- to improve radiological examination reimbursement strategy;
- to integrate in e-health system of the Baltic States;
- to cooperate more efficiently with the Baltic State and other institutions, organizations of radiology;
- to collaborate with European radiological institutions (ESR; UEMS);
- to further improve continuing education and a certification and recertification system in radiology and integration in EU.



## Lithuanian Radiologists' Association

**Jurate Dementaviciene** – President of the Lithuanian Radiologists' Association

The very beginning of radiology in Lithuania dates back to 1896 when the first roentgenodiagnostic equipment was installed. At that time doctors- radiologists were trained in Vienna, Berlin and St. Petersburg.

In 1945 a radiology center was set up at the Lithuanian Ministry of Health and Dr. Vladimiras Krotovas started to work as the chief radiologist of the country. With his initiative the Vilnius Radiologists' Society was established in 1947 and V. Krotovas acted as its leader until 1962.

The societies initiated conducting of training courses for training radiologists and radiology technologists since 1948, which were completed by 13 medical doctors and 30 technicians.

During the following years radiologists' societies were established in other major cities: Kaunas, Klaipeda, Siauliai, Panevezys. All these five regional societies joined to form the Lithuanian Radiologists' Society in 1963. The chairman of it from 1963 to 1972 was Prof. V. Lapinskas, and from 1972 to 1990 Prof. K. Ambrozaitis.

In 1990 the Society was reorganised into the Lithuanian Radiologists' Association and it incorporated societies of specialists of ultrasound specialists and nuclear medicine, and radiology technicians. The president of the society from 1990 to 2006 was Dr. K. R. Dobrovolskis and from 2006 until now Dr. J. Dementaviciene.

At present the structure of the Association is again being reorganised. Radiology technicians formed a separate society in 2007 and joined the corresponding European organisation. The LRA has 365 members - radiologists from all the country. It is formed by regional societies and the structure is composed of the sections according to radiology subspecialties, international relationships, education, telemedicine. Elections are held every three years. Regional societies organise scientific meetings monthly and all-Lithuanian conferences take place every year. Starting from 2006 Baltic Radiology Congresses take place every two years in different Baltic countries and the 1st International Baltic Congress was held in Kaunas, Lithuania, in 2006.

The main activities of the Lithuanian radiologists' Association include continuous improvement and follow up of regulatory documents for radiology service through participation in working groups, designing of projects and proposals for the Lithuanian Ministry of Health in close collaboration with the Radiology Protection Center. The LRA supports and participates in monthly regional meetings, its members organise seminars and conferences devoted to special topics, present novelties in radiology.

We keep close contact with other radiology societies. Our radiologists are individual members of ESNR, ESGAR, RSNA, ISMRM, EAR and other organisations. The LRA joined the EAR in 2008. Also, we are in continuous contact with radiology specialists from other countries, such as the USA, Germany,



Sweden, the UK, France, Austria, Poland etc. In close international cooperation the School of Magnetic Resonance was organised two times in Vilnius; we were granted an International Visiting Professors' Programme by the RSNA in 2006. Invited lecturers participate also in our annual meetings.

We are most proud of contacts with our neighbouring radiologists' societies – Latvian and Estonian. The outcome of these contacts is the 2nd Baltic Congress of Radiology. We wish success and pleasant meeting to the organisers and to all participants.

## Leiomyosarcoma of inferior vena cava

**E. Bieliuniene, G. Kavaliauskiene, D. Mitraite, E. Jonaitiene, A. Basevicius, V. Krasauskas, D. Pranys, S. Lukosevicius, E. Juodzbaliene** – Kaunas University of Medicine, Lithuania

Venous leiomyosarcoma is rare mesenchymal tumour usually affecting the inferior vena cava (IVC). Early diagnosis is essential prior to surgical resection, which is the

only therapeutic modality that prolongs patients' survival. US, CT and MRI are the main imaging modalities in this case. Combined with guided biopsies they form the mainstay of reliable diagnosis. We describe a case with a retroperitoneal tumour arising from the middle segment of the IVC. Radiological examination revealed retroperitoneal tumour. Histopathological examination confirmed the diagnosis of leiomyosarcoma of IVC.

## Correlative analysis of sagittal vertebral radiographic variables in patients with low back pain and in healthy persons

**U. Bucinskas, R. Gleizniene, K. V. Ambrozaitis** – Kaunas Medicine University, Lithuania

**BACKGROUND AND OBJECTIVES.** There are a number of factors that can cause low back pain. We aimed to identify differences in sagittal vertebral radiographic parameters between patients with low back pain and healthy persons.

**MATERIAL AND METHODS.** We analysed the spinal computed tomography of 217 patients (106 male and 111 female) (mean age  $46.1 \pm 10.9$  years) with low back pain. The control group consisted of 52 patients (22 male and 30 female) (mean age  $48.7 \pm 13.2$  years), who had undergone computed tomography of the ab-

domen and pelvis. Selected patients were between 20 and 70 years of age, without spine trauma anamnesis, spondylolisthesis and strongly expressed degeneration. The object of investigation was the central sagittal view of lumbosacral L2-S2 spine. Main measurements were vertebral inclination, sacral inclination, lumbar lordosis, distal lordosis, intervertebral disc index and vertebral body index. All measurements were made using DicomWorks version 1.3.5. Statistics were calculated using Microsoft Office Excel 2003.

**RESULTS.** We found that sacral inclination in females with low back pain is lower than in normal females ( $p=0.023$ ). Comparison of the males and females revealed that male patients with low back pain have lower L3.

## A case of hypertrophic olivary degeneration after succesful treatment of mesencephalon brain abscess

S. Dzelzite, U. Raits, J. Stukens –  
P. Stradina University Hospital, Riga, Latvia

**PURPOSE.** Hypertrophic olivary degeneration is rare radiological finding of unique type of transneuronal degeneration, usually caused by primary lesions in the dento-rubro-olivary pathway, such as ischemic infarction, demyelination, hemorrhage, cavernous hemangioma. We report a case of hypertrophic olivary degeneration diagnosed 6 months after treatment of brainstem bacterial abscess.

**CASE REPORT.** A 67- year- old man presented with symptoms of subacute left side motor and sensory disturbances, extrapyramidal signs and symptoms of sepsis. MR examination of the brain was performed. Examination technique: 1.5 T SIEMENS MAGNETOM Symphony, T1 SE – TR 400/TE 8,7;T2 FSE – TR 4610/TE 127; FLAIR – TR 9000/TE 130/TI 2500; slice 5 mm, gap 1 mm; FOV 230 mm; T1 SE after contrast 0.1 mmol/kg administration. DW single shot, spin-echo, echo-planar sequence b=0, b=500 and b=1000

s/mm<sup>2</sup>, TR 5100,TE 147, NEX-1, matrix 128x128, FOV 250 mm, slice 5 mm, gap 1 mm were used. Typical brainstem abscess 2.1x1x2.5 cm with thin capsule and large zone of perifocal edema was found in right side of mesencephalon. ADC values of content were low, 0.48 x10<sup>-3</sup> mm<sup>2</sup>/sec, a typical findings of bacterial abscess. Systemic antibacterial treatment was unsuccessful and transventricular puncture of abscess through the fourth ventricle was performed and the patient's neurological status improved rapidly. After 6 months the patient presented with brain stem and cerebellar dysfunctions. MR examination with the same protocol revealed residual linear enhancing structure in the previous abscess site, slight hemiatrophy of mesencephalon and bilateral T2, FLAIR hyperintense inferior olivary nuclei with hypertrophy only on ipsilateral side.

**CONCLUSION.** Bacterial infection in mesencephalon can lead to secondary degeneration of inferior olivary nuclei with an asymmetric pattern of hypertrophy which is more pronounced on ipsilateral side

## Role of magnetic resonance diffusion and ADC values in diagnostics of brain tumour

S. Dzelzite – P. Stradina University  
Hospital, Riga, Latvia

**PURPOSE.** To measure ADC values in different primary and secondary brain tumours: extra axial meningiomas, neurinomas, intra axial low and high grade gliomas and other tumours such as ependymomas, medulloblastomas, lymphomas, metastases. To compare

ADC values of peritumoral edema in primary glioblastomas and metastases.

**MATERIALS AND METHODS.** 274 patients underwent brain MR examination. Diagnosis was confirmed at surgery or by stereotactic biopsy, immunohistochemistry analysis was performed. Grading of tumours was based on WHO classification. Technique: 1.5 T SIEMENS MAGNETOM Symphony, T1SE

– TR 400/TE 8.7; T2FSE – TR 4610/TE 127; FLAIR – TR 9000/TE 130/TI 2500; slice 5 mm, gap 1 mm; FOV 230mm; T1SE after contrast 0.1 mmol/kg administration. DW single shot, spin-echo, echo-planar sequence  $b=0$ ,  $b=500$  and  $b=1000$  s/mm<sup>2</sup>, TR 5100, TE 147, NEX-1, matrix 128x128, FOV 250 mm, slice 5 mm, gap 1 mm were used. ADC maps were generated automatically. Measurements of 3 ROI (0.13 – 0.2 cm<sup>2</sup>) in tumour's solid part, contralateral brain, peritumoral edema (when present) were made. Completely cystic, calcified tumours and hemorrhagic region were excluded.

**RESULTS.** The following measurements were made: 8 brain abscesses (ADC=  $0.42 \pm 0.06 \times 10^{-3}$  mm<sup>2</sup>/sec), 41 meningiomas (ADC=  $0.77 \pm 0.11 \times 10^{-3}$  mm<sup>2</sup>/sec), 16 schwannomas (ADC=  $1.33 \pm 0.15 \times 10^{-3}$  mm<sup>2</sup>/sec), 5 lymphomas (ADC=  $0.49 \pm 0.06 \times 10^{-3}$  mm<sup>2</sup>/sec), 5 medulloblastomas (ADC=  $0.62 \pm 0.04 \times 10^{-3}$  mm<sup>2</sup>/sec), 29 astrocytomas grade II (ADC=  $1.57 \pm 0.32 \times 10^{-3}$  mm<sup>2</sup>/sec), 31 anaplastic astrocytomas III (ADC=  $1.04 \pm 0.23 \times$

$10^{-3}$  mm<sup>2</sup>/sec), 55 primary glioblastomas IV, 11 gliosarcomas IV (ADC=  $0.90 \pm 0.19 \times 10^{-3}$  mm<sup>2</sup>/sec), 26 metastases (ADC=  $0.91 \pm 0.16 \times 10^{-3}$  mm<sup>2</sup>/sec), 6 ependymomas (ADC=  $1.47 \pm 0.23 \times 10^{-3}$  mm<sup>2</sup>/sec) 8 anaplastic ependymomas (ADC=  $0.92 \pm 0.35 \times 10^{-3}$  mm<sup>2</sup>/sec) ADC of 15 secondary glioblastomas and 16 other tumours were measured. Median ADC values of peritumoral edema in GBM  $1.37 \pm 0.31 \times 10^{-3}$  mm<sup>2</sup>/sec, in metastases  $1.62 \pm 0.33 \times 10^{-3}$  mm<sup>2</sup>/sec.

**CONCLUSION.** ADC is a quantitative measurement of diffusion. ADC is useful for structural characterization of the pathology. ADC values have direct correlation with tumour cellularity. ADC values differ for low and high-grade gliomas (the latter have equal or lower values compared to brain tissue). For primary CNS lymphomas, ADC values ~50–60% of normal brain, lower than for other tumours, but higher than for bacterial abscesses of the brain. ADC measurements have some limitations: artifacts from calcification, blood products, bone and air.

## Changes in cerebral and visceral blood flow velocities in asphyxiated term infants with hypoxic-ischemic encephalopathy

P. Ilves, M. Lintrop, K. Asser, I. Talvik, M. Veinla, K. Muug, P. Kool, L. Maipuu, T. Metsvaht – University of Tartu, Tartu University Hospital, Estonia

**BACKGROUND.** Severe birth asphyxia is likely to cause disturbances in a number of organ systems other than the brain. The severity of the organ injury is determined in part by the duration of the insult and by the adaptive ability of the foetus to respond to hypoxic-ischemic insult. So far there are no good markers for severity of hypoxic-ischemic injury available during the first hours after asphyxia.

Precise clinical assessment may also be complicated, especially in infants who need mechanical ventilation and sedation.

A number of studies have followed changes in cerebral blood flow velocity (BFV) in different cerebral arteries in asphyxiated infants with hypoxic-ischemic encephalopathy (HIE) during the acute reperfusion phase within the first week after asphyxia. However, there are no data about changes in BFV in visceral arteries after birth asphyxia. Progressive increase in cerebral and visceral BFV occurs in normal infants after the neonatal period but few data are available about long-term BFV changes in asphyxiated infants with HIE after the acute period of recovery.

**OBJECTIVE.** To evaluate long-term changes in Doppler blood flow velocities in cerebral and visceral arteries in asphyxiated term infants during the first days after asphyxia and later during infancy and to establish the relationship between cerebral blood flow velocity, head growth and brain ultrasonography findings in asphyxiated infants with HIE.

**PATIENTS AND METHODS.** A longitudinal prospective study (study group I) was performed in the Children's and Maternity Clinics of Tartu University Hospital. Patients with signs of foetal distress and Apgar scores  $\leq 3$  at the 1st and  $\leq 6$  at 5th min of life, admitted between 1996 and 2003 consecutively in the third-level neonatal intensive care unit before the age of 24 hours were included. BFV was measured in 83 asphyxiated and 115 healthy term infants in anterior (ACA) and middle cerebral (MCA), basilar (BA) and internal carotid artery (ICA). In 2000–2003 BFV was measured both in ACA, MCA, BA and ICA and celiac (CA), superior mesenteric (SMA) and renal arteries (RA) in 47 asphyxiated and in 37 healthy term infants (study group II). Serial ultrasonographic examinations and BFV measurements were made on admission (before the 24 h of life) and at least three times during the first 10 days of life, thereafter once a week until discharge and afterwards at least twice during the first six months of life. The severity of hypoxic-ischemic encephalopathy was evaluated during the first week of life and psychomotor development and the head circumference of infants was followed for 18 months.

**RESULTS.** Study group I. Mean cerebral BFV increased significantly ( $p < 0.001$ ) during the first week after asphyxia in infants with severe HIE ( $n=25$ ) compared to the control group or infants with mild to moderate HIE ( $n=58$ ). Maximum values were found at the age of 36–71.9 h: in ICA (mean (95% CI)) 31.2 (25.5–36.6) cm/s in severe HIE infants compared to 13.0 (12.2–13.9) cm/s in con-

rols. In infants with mild/moderate HIE or in infants with normal outcome/mild impairments mean BFV was also higher than in the control group in all cerebral arteries during the period 36–120 h ( $p < 0.05$ ) and in ACM and ACA also during the period 148–240 h. Decreased ( $p < 0.05$ ) mean cerebral BFV developed in infants with severe HIE by the age of 21–59 days: in ICA 14.1 (11.5–16.8) cm/s compared to 22.9 (21.4–24.4) cm/s in controls. In the group of mild/moderate HIE and also in asphyxiated infants with normal outcome/mild impairments mean cerebral BFV increased progressively in all investigated cerebral arteries during the first months of life similarly to the control group. Infants with severe HIE had similar mean height but lower head circumference and mean BFV compared to controls ( $p < 0.05$ ) at the age of 21–59 days.

Study group II. In infants with severe HIE mean BFV in RA was significantly decreased ( $p < 0.05$ ) during the first 10 days after asphyxia, most severe decrease in BFV was seen at the age of 24–35 h. In infants with mild-moderate HIE mean BFV in SMA and CA were significantly increased ( $p < 0.05$ ) compared to the control group during the first 12 h after asphyxia. In infants with severe HIE such compensatory hyperemia was not found and a significant decrease in mean BFV in SMA, compared to the control group, was measured at the age of 24–35 h after asphyxia ( $p < 0.05$ ). BFV in all visceral organs normalized in infants with birth asphyxia by the age of 21–59 days.

**CONCLUSION.** Significant changes in cerebral and visceral BFV occur during the first week after asphyxia in asphyxiated infants with severe HIE and poor prognosis. The high mean cerebral BFV found in infants with severe HIE during the first days after asphyxia is temporary and low cerebral BFV and head circumference develop by the age of 21–59 days. Mean BFV in all visceral arteries normalizes by the age of 21–59 days in infants with HIE.

## Radiological and neurodevelopmental outcome in infants with inflicted traumatic brain injury (shaken baby syndrome)

P. Ilves<sup>1</sup>, M. Lintrop<sup>1</sup>, I. Talvik<sup>1</sup>, A. Sisko<sup>2</sup> –

<sup>1</sup>University of Tartu, Tartu University Hospital, <sup>2</sup>North Estonia Medical Centre

The diagnosis of inflicted traumatic brain injury (ITBI) is usually based on clinical and radiographic findings. Injuries that characterize inflicted brain injury are intracranial and retinal haemorrhages, rib fractures and metaphyseal corner fractures of long bones. Imaging of the central nervous system is especially important and can demonstrate subdural and/or subarachnoid haemorrhage, diffuse or focal cerebral oedema, or cerebral contusions. Several studies show acute changes in ITBI on admission but there is limited information available on long-term radiological and clinical outcome of these infants.

**THE AIM** of this study was to characterize long-term radiological findings in infants with inflicted traumatic brain injury.

**METHODS.** During the period between January 1, 1997 and December 31, 2003, 26 cases of ITBI were identified in Estonia within a population-based prospective study. The diagnosis of ITBI was made on the clinical and physical findings (including ophthalmological examination), a combination of radiological imaging, interviews with the children's caretakers, and investigations of the trauma mechanism. The radiological follow-up was performed with 2 or 16 slice CT or 1.5T MRI scans in regional hospitals (Tartu University Hospital and North Estonia Medical Centre) during the acute phase of injury (48h), during the early postinjury phase (at least 3 days up to 3 months after injury), and during the late postinjury phase (at least 9 months after injury). All radiological investigations were retrospectively reviewed by two radiologists.

**RESULTS.** Of 26 patients with ITBI 24 passed also radiological investigations, 2 died without radiological investigations. All infants were less than 1 year old, only 6 were girls. All patients had unilateral (n=6) or bilateral (n=18) subdural haematoma on admission. Nine patients (38%) had only acute subdural haematoma, 3 had only subacute haematoma and 6 had chronic haematoma but 6 (35%) patients had mixed-density convexity subdural haematoma indicating different ages of the haemorrhage. The subdural haematomas were mostly large, in 18 infants frontotemporoparietal or over the whole hemisphere. Thirteen of 24 patients (54%) had also interhemispheric blood, all but two with acute haemorrhage, 13 patients (54%) had subarachnoid blood, 7 patients (29%) had blood on tentorium, all with acute subdural hematoma, 13 (54%) had subdural blood high up on calvarium. Intraparenchymal focal contusions predominated in the frontal and temporal regions and were found in 10 of 24 patients (41%), in 6 of them in subcortical white matter, in 3 of them foci were also in cortical grey matter and in 2 patients in deep grey matter. Eight infants had general brain oedema during the acute stage, but 3 had oedema in different vascular regions in several lobes, 4 bilaterally in basal ganglia, 5 infants had low attenuation only in some regions of white matter. Skull fractures were noticed only in 2 patients. In 19 (79%) of infants signs of earlier brain damage/ pre-existing brain abnormality, including cerebral atrophy, subdural hygroma and ex vacuo ventriculomegaly were seen on admission.

Early follow up with MRI (n=7) and CT (n=15) was available in all 22 survivors and showed substantial resolution of the initial lesions. New changes were found in 9 infants: 2 infants had a new haemorrhage, gliotic changes appeared already in 3 patients and multicystic

degeneration had developed in 4 infants. In all infants signs of atrophy were visible: in 16 infants mild to moderate mostly frontotemporal atrophy and in 6 infants (27%) general severe atrophy had developed. Five infants had lost almost all white matter and 11 had decreased amount of white matter in some regions.

Late radiological investigations more than 9 months after injury (mostly MRI) were performed in 19 of 22 survivors (86%). The number of infants with focal hyperintensities in white matter had increased from 3 to 14 (63%) and 4 more patients had multicystic degeneration of the brain (all seen also early postinjury). Seven infants had very thin corpus callosum, which was smaller compared to the base-line

investigation in 5 patients; atrophic hippocampus was found in 6 patients. Four patients had developed hyperintense focal changes in basal ganglia, one patient had general atrophy and one had calcifications. Seven infants had developed severe brain atrophy, 9 mild to moderate frontotemporal brain atrophy and only in 3 patients' signs of atrophy were minimal at follow-up. Of twenty-two survivors only two had no developmental problems at follow-up, 20 of 22 children had different developmental problems, 3 of them were severely handicapped.

**CONCLUSION.** The radiological and neurodevelopmental outcome in these potentially healthy children is poor.

## Multi-detector computed tomography (MDCT) angiography value in diagnosis of gastrointestinal (GI) bleeding

G. Kavaliauskiene, A. Basevicius –  
Kaunas Medical University Hospital,  
Lithuania

**BACKGROUND AND OBJECTIVES.** Diagnosis and treatment of acute GI bleeding is a complicated problem requiring collaboration of many specialists. There are a number of different diagnostic modalities to choose from in solving this clinical problem. The aim of our study was to illustrate the role of MDCT in the diagnosis of GI bleeding, especially in traumatic patients and in planning of interventional procedures.

**MATERIAL.** All our patients were investigated with GE Lightspeed 16-slice CT scanner. Administration of 150 ml of non-ionic contrast medium intravenously was performed. Arterial phase contrasted images were acquired with a slice thickness of 0.625 mm to determine direct signs of bleeding. Precontrast and portal phase contrasted images were important to evaluate indirect signs of bleeding and the condition of other abdominal organs.

**METHODS.** MDCT angiography is a specific, sensitive, non-invasive imaging modality to detect GI bleeding signs, their site and cause, to evaluate blood vessel course, injury of parenchymal organs in traumatic patients. Endoscopy is usually a procedure of choice for GI bleeding detection, but there is limitation in evaluation of small bowel and traumatic patients. Scintigraphy is a long lasting and not widely available method. Angiography is also a diagnostic and treatment modality, but it is an invasive procedure, for better results additional information about arterial anatomical variants is required.

**RESULTS.** MDCT angiography is an imaging modality of choice to diagnose GI bleeding when endoscopy failed or is negative. CT can reveal other pathology, especially in traumatic patients, gives important additional information for interventional procedures even if no direct signs of GI bleeding were present. It ensures better diagnostics and treatment results and better patient prognosis.



## Preoperative CT diagnosis in pancreatic cancer

T. Kuum, P. Ilves, S. Ulp, O. Tammik –  
Tartu University Hospital, University of  
Tartu

Pancreatic cancer accounts for about 2–2.5% of all primary cases of cancer but almost 6% of all cancer deaths (America Cancer Society, 2007) with very low, 5-year, survival rate (4%). In case of early cancer detection, survival is about 10–35% (Jemal et al., Cancer Statistics, 2004. CA Cancer J Clin, 2004). Main clinical signs of pancreatic cancer are: loss of body weight more than 10%, abdominal pain and jaundice appear late and about 90% of primary cases are already locally advanced or have metastases in the liver or lungs. Radiological investigations are important in the diagnosis of pancreatic cancer. Ultrasound investigation as a cheap and widely available method is usually the first investigation. Multislice computed tomography (CT) with different reconstructions is suggested to evaluate the stage of pancreatic cancer and possibilities of operation.

**THE AIM** of the study was evaluation of correlation between CT descriptions and findings during operation and histological investigation.

**MATERIALS AND METHODS.** Retrospective evaluation was performed during the period between 01. 01. 2007 and 30. 06. 2008. In all 32 cases of pancreatic cancer operated in Tartu University Hospital with available both preoperative CT investigations and histological material confirming the diagnosis of

pancreatic cancer. CT was performed with 2-slice Siemens Somatom (2000) and 16-slice GE LightSpeed 5X Pro16 (2005). The size and contrast enhancement of the tumor, enlargement of lymph nodes, metastases in the other organs, enlargement of pancreatic duct and biliary tree, involvement of the duodenum, peripancreatic tissue and vessels were evaluated.

**RESULTS:** Only in 16 of 32 patients (50%) CT descriptions correlated fully with the findings obtained during operation. Metastases, bile duct and pancreatic duct were described in 30 of 32 cases and the finding was similar to that obtained during the operation in 83% and 96% of cases, respectively. Duodenum and peripancreatic tissue was described only in 20 of 32 patients (63%) and involvement of blood vessels in 15 of 32 patients (47%). Only in 60% and 65% of described cases, respectively, the findings were similar to those obtained during operation. The mean time between performed CT and operation was 21 days (with min-max 1 – 60 days).

**CONCLUSIONS.** Precise description of blood vessels and involvement of the duodenum and peripancreatic tissue are important for planning operation in pancreatic cancer patient. If the period between CT and operation is too long (more than 21 days) a new CT may be necessary to evaluate the possibilities for radical operation.

The study was supported by grant SF0180161s08



## Risk factors of hip dislocation after primary total hip replacement (THR): clinical and radiological analysis

P. Likums, G. Krumina, P. Studers –  
Hospital of Traumatology and  
Orthopaedics, Riga, Latvia

**PURPOSE.** According to literature data hip dislocation occurs in 2-9% patients after primary THR. Most commonly it is caused by component malposition, soft tissue disbalance etc. The purpose of our study was clinical and radiological analysis of the risk factors determining hip dislocation after THR.

**MATERIALS AND METHODS.** We retrospectively analysed 2626 THR cases treated at the Hospital of Traumatology and Orthopaedics (HTO) in the period of 2000–2003. We found 59 hip dislocations (20 in male and 39 in female patients). In clinical analysis we included surgical diagnosis, patient condition, leg length, surgery data, and cause of dislocation. Radiological analysis included: plain x-ray of pelvis; hip AP,

LL (before surgery, after surgery, dislocation, reposition, revision surgery); lumbar spine AP, LL; CT scan according to evaluation protocol. For data evaluation SPSS were used.

**RESULTS.** In our hospital (2000–2003) hip dislocation had occurred in 2.2% of primary THR cases. Clinical results. Early postoperative dislocations (up to 6 weeks) 28.8%; late and recurrent dislocations 86.4%; indirect risk factors: alcohol 35.6%; mental disorders 8.5%; previous surgery 16.9% of dislocation cases. Radiological results. Acetabular component malposition was found in 35.6% of dislocation cases.

**CONCLUSIONS.** 1) Dislocation rate. In our clinical and radiological analysis we found it to be 2.2%. This result corresponds with the data of literature. 2) The main risk factors were previous surgery of hip, alcohol abuse, mental diseases and implant's malposition.

## Evaluative function of cardiac MDCT of the right ventricle

M. Mataciunas, D. Zakarkaitė,  
A. E. Tamosiunas, N. Valeviciene – Vilnius  
University Hospital Santariskiu Klinikos,  
Vilnius, Lithuania

Recent advances in multidetector computed tomography (MDCT) techniques with dramatically improved temporal resolution inspired great interest in the possibility to visualise a constantly moving organ like heart. Advent of MDCT with ECG gating enabled noninvasive quantification of cardiac function. Meas-

urements of right ventricular (RV) volume and function provide important information for the diagnosis, treatment, follow-up, and prognosis of various cardiac and pulmonary diseases. Noninvasive techniques such as radionuclide ventriculography, MRI, and echocardiography have been used for the evaluation of RV function, but not without limitations. Complex shape of the right ventricle makes assessment of ventricular function difficult. In our presentation we give an overview of the advantages and limitations of ECG gated MDCT to noninvasively quantify RV function.

## First radio-immunotherapy with Zevalin in Estonia

**S. Nazarenko, A. Šamarin, M. Varik,  
R. Rooneem, L. Karusoo, M. Paris,  
S. Soosaar, E. Järv, V. Vahter** – North  
Estonia Medical Centre

First radio-immunotherapy (RIT) with Zevalin was performed in Estonia on 28 February 2008 at the North Estonia Medical Centre.

The aim of the present paper is to present this clinical case and to provide information on the background of RIT with Zevalin.

Therapeutic use of Zevalin (90Y-radiolabelled ibritumomab tiuxetan) for the treatment of follicular B-cell Non-Hodgkin Lymphoma (NHL) started in clinical trials about ten years ago and was approved in Europe by EMEA in January 2004 for treatment of adult patients with rituximab-relapsed or -refractory CD20+ follicular B-cell NHL.

For radio-immunotherapy (RIT), careful selection of patients is essential, including clinical tests to reveal indications and contra-indications. In our case workup included clinical, laboratory and imaging studies, incl. PET/CT.

In RIT with Zevalin successful ex tempore labeling of monoclonal antibodies with radioactive yttrium plays a key role for the success of the treatment. Therefore, during the period of 9 months prior to the therapy session careful preparation of radiopharmacy was undertaken, installation of radiation protection tools and training of the personnel were carried out.

The patient who was identified for RIT was 49 years old, male. In 2003 follicular B-cell NHL t(14;18) bcl-2 positive was diagnosed. In 2004, after 8 sessions of CHOP+rituximab remission was achieved, confirmed by positron emission tomography (PET) in 2004 at our institution. The first relapse was diagnosed in 2005, when enlargement of mediastinal lymph nodes was observed in CT. After radiotherapy,

remission was achieved. In 2006 PET/CT revealed two moderately enlarged metabolically active inguinal lymph nodes on the right side without clinical and laboratory signs of progression. The second relapse was diagnosed in 2007 and documented by PET/CT. In PET/CT multiple metabolically active enlarged lymph nodes were seen in the left parailiacal and inguinal regions – the finding corresponded to active disease. Molecular-genetic investigation of bone-marrow aspirate revealed t(14;18) bcl-2 positivity again.

As no contra-indications were found, in November 2007 an ex consilio decision was made to perform RIT with Zevalin.

In January 2008 a pre-treatment PET/CT was performed and significant disease progression was shown, including involvement of multiple bilateral supradiaphragmatic and infradiaphragmatic lymph nodes.

RIT was performed in concordance with the “EANM procedure guideline of radio-immunotherapy for B-cell lymphoma with 90Y-radiolabeled ibritumomab tiuxetan (Zevalin)” taking into consideration all requested safety precautions. As it was our first procedure, an emergency team was available for any allergic or other potentially harmful reactions.

In our patient the procedure was well tolerated and no significant extraordinary side effects were observed. After a three-month period of clinical and laboratory observation by the hematologist no metabolically active lymph nodes were discovered on PET/CT. The dimensions of lymph nodes were considerably decreased corresponding to complete response to therapy. Bone marrow was free of infiltration, molecular-genetic investigation was negative. According to these findings complete remission was achieved.

On the basis of our experience we conclude that in Estonia the first RIT with Zevalin was successful. The key factors of our

success were good collaboration between the specialists of hematology and nuclear medicine, careful selection of the patient

and thorough preparation for RIT. PET/CT significantly contributed to the diagnosis and follow-up of the patient.

## Golden rules for management of an imaging department

**S. Nazarenko** – North Estonian Medical Centre, Tallinn, Estonia

Estonia is a country with a relatively small population that has survived invasions of numerous political, economic and religious powers. It has been fully independent only for a total of almost 40 years during the period of the last 1700 years. After 1991, during our second independence, Estonian radiology rapidly passed the period of transition and today it offers up-to-date imaging services not only for local recipients health care but also for foreign recipients arriving here, and via links of telemedicine.

As we see, in Estonia the historical background may predestinate cool reception of any attempt to set rules or instructions for any area of life. However, once established, these rules and instructions are either followed with zealous precision, or are boldly bypassed through any legal loophole. Consequently, we do not have any rules or instructions developed by or handed down to radiologists in advance before introducing any changes that would have ensured our success. These rules and instructions were compiled during the process of transition and they can be identified as success factors through retrospective analysis. They are:

1. Permanently think of radiology and manage the radiology department for the benefit of people (patients, professionals,

clinical partners, other interest groups, society).

2. Always aim at the latest technologies.
3. Keep a balance between personnel, technologies, available skills and knowledge.
4. Observe the development of the current environment and try to influence its changes.
5. Remember the “clash of civilizations” and be aware of eventual characteristics of the organizational culture.
6. If you feel there is a lack of money, then you simply have not bothered to pick it up. The reward for investing into radiology is paid back in clinical wards and at the homes of recovering patients.
7. There are no limits or barriers, because they only exist in our minds.
8. Link individual goals to the business’ overall goals. Allow colleagues to fail and reward their success. Evaluate your partners on the basis of their actual results, not your personal feelings.
9. Keep problems separate from persons.
10. Don’t build your luck on the ruins of other people’s luck.

We strictly believe that in the modern world we may share a variety of aspirations, but everyone has to take his/her own path and commandments to reach the common goals. Hopefully, our experience may provide some encouragement for identifying own values, rules and commandments for managing an Imaging Department in different settings.

## Importance of x-ray, CT and MR in the diagnosis of osteoporosis

**A. Platkajis** – Riga Stradins University,  
Riga Eastern Clinical Hospital “Gailezers”,  
Latvia

Osteoporosis is a disease characterized by low bone mass and loss of bone tissue that may lead to weak and fragile bones. The most accurate method for detecting and for quantitative analysis of osteoporosis is dual energy X-ray absorptometry (DXA). X-ray, computed tomography (CT) and magnetic resonance imaging (MRI) are radiological methods to evaluate changes in bone structure, to diagnose complications of osteoporosis (fractures) and to differentiate it from other diseases. Historically, X-ray is the first radiological method for bone structural analysis and it has an important role in diagnosis of bone pathology nowadays. This modality is widely available and is less costly when compared to the other imaging modalities like MRI or CT.

The absorption of x-ray by tissue depends on the quality of x-ray beam and character of atoms composing the tissue, the physical density of the tissue, and thickness of the bone. X-ray visualizes well trabecular and cortical bone and structural changes in the bones. In case of osteoporosis x-ray evaluates increasing radiolucency of bone, cortical bone remodeling due to decrease of total calcium level, and fractures. The most typical sites of fractures related to osteoporosis are the spine, hip, wrist and ribs, although the disease can affect any bone in the body. Currently mild and moderate vertebral fractures are often not being recognized and reported, leading to underdiagnosis and under-treatment. Assessment of vertebral fractures on x-ray films can be done visually and morphometrically.

Visual radiologists are able to detect anatomical variants of vertebral bodies, non-osteoporotic deformities and non-osteoporotic changes of bone structure. The result is sub-

jective, depends on the radiologist's experience and training. Plain film morphometry is quantitative technique to measure vertebral dimensions and can provide more objective information about vertebral height.

CT is a widely available diagnostic technique used for all types of indications. In addition to morphologic information, CT provides information about the attenuation of the tissues studied. CT is a sensitive method for imaging bone structural changes, including fractures and soft tissue changes. On CT axial images and reconstruction images provide better visualization of vertebral fractures, deformities, intraarticular fractures, influence of fractured parts of vertebral bodies on dural sac compared to visualization on plain films.

Quantitative CT is a highly sensitive, quantitative measuring technique to assess bone density. The advantage of quantitative CT is its ability to measure either trabecular or cortical bone in the central or peripheral skeleton. The method provides precise three- dimension anatomic localization of bone structures allowing direct density measurement of trabecular bone separately from cortical bone. Trabecular bone has high metabolic turnover, and changes in mineralization or in the amount of bone is measurable more easily with techniques that can selectively measure trabecular bone.

In recent years MRI has become an applied method for evaluation of vertebral fracture and for detection the reason for this fracture. Using spin echo, inversion recovery sequence, and diffusion weighted images, the radiologist can differentiate benign vertebral collapse from malignant collapse. MRI evaluates dislocation of vertebral parts in spinal canal or intervertebral foramina, size and localization of soft tissue mass in case of malignant compression fracture.

In some studies MRI has been performed for assessment of bone trabecular structure.

Mineralized bone elements can be assessed using T2\* decay characteristics that measure field inhomogeneities caused by susceptibility differences at the marrow – bone boundaries, using high-resolution MRI. Trabecular bone

structure may be quantified directly using a computer – based analysis software.

MRI is an informative method for evaluation of transient osteoporosis and diseases which change bone marrow signal.

## Ultrasonography in diagnosis of renal tuberculosis

**M. Radzina, E. Kadakovska, I. Simanovica** – State Agency of Tuberculosis and Lung Diseases, Latvia

**AIM.** The aim of the present study is to determine the essential features of ultrasound (US) in renal tuberculosis (RTB) and evaluation of treatment efficiency.

**MATERIAL AND METHODS.** During the 5-yr period (2003–2007), 60 cases of proven urogenital tuberculosis were analyzed (6% of extrapulmonary TB in Latvia). US examination (including color doppler) was performed for all patients according to our hospital protocol: during the acute phase of the disease, during active treatment and after full recovery. 40% of the cases had follow-up US. Examinations were performed by 3 radiologists and according to the follow up protocol each patient was examined by the same specialist to minimize interpretation differences. The special approach was used for kidneys, collecting system and urine bladder (size, shape, structure and obstruction level). Diagnosis was proved clinically and by laboratory tests in all cases.

**RESULTS.** Age range was 33–84 years, in majority of cases 50–70 years. 68.3% (41 case) of renal primary active TB location and 31.66% (19 cases) had this form as a second TB location (primarily lung or generalized TB form).

No differences were found between the sexes. There were no pathologic US findings in 32% of cases, but 43% had severe renal pathology (diffuse parenchyma lesion, cavitations, hydronephrosis, end stage renal impairment) and 25% had residual changes like cysts, scarring, calculi, size reduction. 11 cases had combined (RTB and genital) pathology including orchiepididymitis, prostatitis, endometritis. M. tuberculosis test was positive in 35 cases, 18 cases were confirmed histologically, 10 cases were confirmed clinically and radiologically. 3 cases were false positive and 1 case was false negative. More than 50% (32 cases) had total recovery and 3.3% (2 patients) had lethal outcome, rest of the group is still in follow-up stage. Multiple follow-up US that was performed by the same specialist improved the specificity of the method via the accuracy of calculations and interpretation of the dynamics of the process and treatment efficiency.

**CONCLUSION.** The study shows that US is an effective diagnostic method for detection of renal tuberculosis. It has much higher specificity if performed by an experienced specialist, especially in the early stage of the disease. This method requires uniform characteristics of renal lesions in evaluation of treatment. Multidisciplinary (clinical, laboratory and radiology) approach plays a key role in the accuracy of final diagnosis and treatment efficiency.

## Comprehensive view of a medical case is provided for the professionals and patients by seamless integration of electronic health data and images

P. Ross, M. Parve, T. Luumann, P. Siinmaa, E. Valdre – East Tallinn Central Hospital, Estonia

**BACKGROUND AND OBJECTIVES.** Much attention has been paid to the integration of picture archiving and communication system (PACS) and hospital information system (HIS). However, secure distribution of images and reports outside the enterprise remains still an issue. The primary structure of HIS implemented at East Tallinn Central Hospital (ETCH) in 1992 was based on the separate small databases facilitating mainly statistical tasks and calculation of the cost of a medical case. In 2003, problems of archiving and processing of medical data and integration of several application-based databases of HIS to form an electronic patient's record (EPR) were partly solved by implementation of PACS and simultaneous integration it with HIS containing unidirectional data exchange from HIS to PACS. In the same year, HIS was converted to web-based application. In 2007, a new web-based PACS was acquired which improved its integration with HIS. Development of HIS-PACS enabled retrieval of medical data through the single entry also from outside the hospital. We used Estonian nation-wide data exchange platform called x-road to secure the access to EPR from outside of the hospital. Identification of the person accessing EPR was based on the compulsory ID-card issued by the state.

The challenging aim of EPR development at ETCH to enable access to patients' health data and medical images from any location by both health care professionals and patients was successfully fulfilled.

**MATERIALS AND METHODS.** A HIS program Ester 3.4 (AS Gennet Lab, Tartu, Estonia) with web interface E-Terviselugu was used for medical data retrieval. Images were viewed using web based Carestream PACS version 10.3 (Eastman Kodak Company, USA) and Easyviz version 2.6 PACS (Medical Insight A/S, Denmark). Carestream and Easyviz program were linked to Ester program using the URL link POST-GET method using secure https protocol. All components were tested thoroughly during the pilot phase. After that, the contract was drawn up and signed by the parties (GP and ETCH accordingly). Subsequently, the system was introduced into use together with on-site training.

Finally, a questionnaire for GPs containing several performance questions about the system was executed.

**RESULTS.** By the end of May 2008 there were 69 GPs who had signed the contract with the hospital for web-based viewing of medical images and reports. This gave GP legal right to view EPR contents including the results of his/her patients' radiology tests done in the ETCH. During the period of 6 months (01.02.–01.07.2008) GPs have viewed the images of 233 radiology tests 430 times. Almost half of the tests were viewed twice.

**DISCUSSION.** GPs do use the option to view their patients' images through web-based solution. This gives them an opportunity to follow patient's imaging progress independently of the service provider. On average, there were 4 image viewing sessions per working day during the study period. There were no considerable technical or legal issues while integrating HIS-PACS with secure data exchange platform. However, administration of users from outside the hospital brought about additional cost.

**CONCLUSION.** Integration of web-based PACS and HIS enabled access to patient medical data and images from outside the hospital through a single entry. Nationwide data exchange

platform and ID-card was used to secure access. Simple access and the holistic view of patients' medical data were accepted and eagerly exploited by health care professionals.

## Radiological evaluation of early complications of acute pancreatitis

A. Samuilis, D. Rutkauskaite,  
J. Dementaviciene, A. Sileikis – Vilnius  
University Hospital, Lithuania

This study was conducted to assess early complications of acute pancreatitis on CT.

**MATERIALS AND METHODS.** 27 contrast enhanced CT scans of 27 consecutive adult patients with acute pancreatitis examined from 2006 to 2007 in Vilnius University Hospital, Santariskiu klinikos, were retrospectively reviewed (19 male patients and 8 female patients, mean age 44.2  $\bar{x}$ ,  $\pm$  13.7). Inclusion criteria were biliary or alcoholic acute pancreatitis, CT scan was performed not earlier than the 3<sup>rd</sup> day and not later than the 6<sup>th</sup> day after the onset of symptoms, patients were not operated within this period. All CT images were obtained using contrast enhanced helical CT (GE LightSpeed Pro 16 slices or GE VCT 64 slices; pancreatic phase, slice thickness 1,25mm, scan delay 30–35 s; portovenous phase, slice thickness 2,5mm, scan delay 60–65 s). Presence of pancreatic necrosis and necrosis extent, peripancreatic inflammatory changes, fluid collections as ascites and pleural effusions, vascular, parenchymal complications and gastrointes-

tinal tract involvement were evaluated. All CT scans were scored with the Modified CT Severity Index: pancreatitis was graded as mild (0–2 points), moderate (4–6 points), or severe (8–10 points).

**RESULTS.** Pancreatic necrosis was detected in 59.3% of patients (n=16), peripancreatic inflammatory changes in all patients (n=27), ascites in 85.2% (n=23), pleural effusions in 85.2% (n=23; right to left ratio 2:7), vascular complications in 44.4% (in 11 patients compressions or/and thromboses of portal vein trunk, branches, tributaries and in one patient arterial hemorrhage were observed), peri- and pararenal involvement in 92.6% (n=25, right and left ratio 5:8), gastrointestinal complications in 40,7% (n=11, secondary inflammatory changes in small and large intestines). Extrapancreatic parenchymal abnormalities were observed in one patient (it was observed in a liver). CT scans were graded as moderate in 22 scans, severe in 5 scans.

**CONCLUSIONS.** Main complications of early acute pancreatitis are necrosis, pleural effusions (more often on the left side), ascites, peri- and pararenal (more often on the left side), gastrointestinal involvement, compression and/or thrombosis of portal vein system.



## Effectiveness of the Zweymüller prosthesis and radiological evaluation of the survival of the endoprosthesis

P. Sarap<sup>1,2,3</sup>, K. Kirjanen<sup>1,3</sup>, P. Ilves<sup>1,2</sup>,  
A. Märtson<sup>1,3</sup> – <sup>1</sup>University of Tartu, <sup>2</sup>Tartu  
University Hospital, Dept. of Radiology,  
<sup>3</sup>Tartu University Hospital, Traumatology  
and Orthopaedics Clinic, Estonia

Hip arthroplasty is one of the most frequent operations in orthopaedics. The main factor showing the effectiveness of arthroplasty is the survival rate of the endoprosthesis. The cementless Zweymüller prosthesis was introduced in 1979 and has gained considerable popularity.

**THE AIM** of the study was to evaluate survival and radiological outcome of cementless Zweymüller hip arthroplasty in Tartu University Hospital in 1998–2005.

**METHODS.** In a retrospective study the X-ray images of 296 cases were investigated. Only 157 were included in analysis because of the poor quality of the pictures. Radiographic evaluation included pre-, early and late postoperative pictures and determination of FCFI (*Femoral Canal Flare index*), signs of osteolysis, cortical sclerosis, stem subsidence and position of the stem. The age of the patients varied between 15–67 years (mean 44.8 years). The operated patients were followed

clinically; mean time of follow-up was 4.0 years (range 1–9 years). Endoprosthetic survival was analyzed according to the Kaplan-Meier method using prosthetic revision as the endpoint.

**RESULTS.** X-ray changes were detected in 23 cases, in 11 cases endoprosthetic revision was performed, 4 cases demanded a reposition due to luxation, in 1 case with periprosthetic fracture conservative treatment was applied and 7 cases showed radiological changes but no clinical signs. During the follow-up period a revision operation was performed in 3.6%. The reason for revision was aseptic loosening in 3 patients (1.0%), deep infection in 1 patient (0.3%), dislocation in 2 (0.6%), perioperative bone fractures and technical errors of the stem implantation in 4 (1.6%), acetabular problems in 1 (0.3%) case. Significant differences were found in FCFI between complicated and noncomplicated cases ( $p < 0.005$ ). Patients with decreased FCFI by 1 point had 9 times higher risk for complications after arthroplasty (OR 9.094 and 95% CI 1.773–46.187). The survival rate for the uncemented Zweymüller prosthesis was 94.6%.

**CONCLUSIONS.** Patients with low Femoral Canal Flare Index had higher risk for complications after joint replacement with cementless Zweymüller prosthesis.

## The value of measurement of hepatic venous pressure gradient in liver cirrhosis

V. Silkauskaitė, A. Pranculis, D. Mitraite,  
L. Jonaitis, L. Kupcinskas – <sup>1</sup>Kaunas  
Medical University Hospital, Lithuania

**OBJECTIVE.** Portal hypertension is the direct cause of most complications of liver cirrhosis.

Variceal bleeding is a life threatening complication and major cause of death in patients with liver cirrhosis. Main clinical factors associated with the risk of variceal bleeding include liver function (Child-Pugh classification), size of varices and severity of portal hypertension. Measurement of the hepatic



venous pressure gradient (HVPG) is the gold standard technique to evaluate presence and severity of portal hypertension. Variceal bleeding usually occurs when HVPG reaches >12 mm Hg. The aim of the present prospective study was to evaluate relationships between degree of portal hypertension and bleeding status, and severity of liver cirrhosis.

**METHODS.** 128 patients with liver cirrhosis underwent HVPG measurements, endoscopy, clinical and biochemical evaluation. Liver insufficiency was evaluated according to Child-Pugh-Turcotte (CTP) scoring system. Patients with decompensatory cirrhosis (presence of severe ascitis, acute variceal bleeding < 14 days, hepatorenal syndrome, cardiopulmonary disorders, transaminases > 10ULN), active alcohol intake, use of antiviral therapy and/or beta-blockers were excluded from the study.

**RESULTS.** One hundred twenty-eight patients with liver cirrhosis (M:F, 67:61; mean age 53.78 ±12.72 years) were included into the

study. Etiology of cirrhosis was viral hepatitis, alcoholic liver disease, cryptogenic and miscellaneous reasons in 57/49/14/8 patients, respectively. Child A, B and C stages of liver cirrhosis were established in 28 (21.87%)/70 (54.69%)/30 (23.44%) patients, respectively. The difference of mean HVPG was significant for different CTP classes: mean HVPG in Child A class was 13.52 ±5.33 mm Hg while in Child B and C stage liver disease 16.74 ±4.58 mm Hg and 17.29±4.97 mm Hg respectively (p=0.01). 34 patients had an episode of previous variceal bleeding. The difference of established mean HVPG was significantly higher in bleeders (18.67±4.69 mm Hg vs 15.87±4.69 mm Hg; p=0.006) than in non bleeders.

**CONCLUSIONS.** The severity of portal hypertension correlates with progression of liver function insufficiency and risk of variceal bleeding. HVPG measurement is useful in clinical practice when selecting cirrhotic patients at the highest risk of variceal bleeding and referring them for specific therapy.

## Imaging of liver transplantation

**A. E. Tamosiunas** – Vilnius University Hospital Santariskiu Klinikos, Lithuania

Since 1968 when Starzl performed the first liver transplantation it became a widely used common surgical procedure used for treatment of end stage liver diseases and occasionally for hepatic malignancies (1).

Most common is orthotopic liver transplantation of the whole cadaver liver, however, due to shortage of liver donors other techniques are increasingly employed: split liver transplantation when the liver is divided to treat two patients; transplantation of living-donor left lobe (usually 2 and 3 segments) for pediatric patients, and living-donor right lobe in adults (1, 2, 8).

During orthotopic liver transplantation the recipient's liver is removed and all three donor

liver vascular systems and bile duct are connected to those of the recipient, creating at least four vascular anastomoses. Hepatic portion of the IVC of the donor is connected to the recipient's creating two end-to-end anastomoses: proximal (suprahepatic or cranial) and distal (infrahepatic or caudal). Recipient's hepatic part of the IVC is removed with the diseased liver. In case there is a large mismatch between the donor's and the recipient's IVC diameters "piggyback" technique may be used when proximal part of the donor IVC is anastomosed end-to-side to the recipient's spared IVC and the distal part of the donor IVC is closed. When only the right hepatic lobe is transplanted, the right hepatic vein is connected end-to-end to the recipient's right hepatic vein or directly to the IVC. In the left lobe transplantation left hepatic vein anastomosis is performed accordingly (1).

Donor portal vein typically is connected end-to-end to recipient portal vein. If this anastomosis is impossible due to congenital abnormalities or the thrombosis of the main portal vein the anastomosis may be created to other patent portal tributary, usually superior mesenteric vein. In transplantation of the one liver lobe of the donor right or left portal vein is connected to the recipient main portal vein.

Donor hepatic artery is usually mobilized in its maximum length including celiac artery and small aortic patch to connect it to the recipient common hepatic artery. As mentioned previously, anatomic variations of the liver arteries are very common, hence additional anastomoses and interposition grafts may be employed connecting the donor and recipient arterial systems.

Biliary anastomosis is performed end-to-end, usually on a T-tube catheter which is left for a couple of weeks. When the bile duct length is insufficient, which happens when only one lobe of the liver is transplanted from living donors, anastomosis is performed to Roux-en-Y jejunal loop. Bile ducts of the transplanted liver are supplied solely by the transplanted artery, arterial collaterals are absent in early stages after transplantation, so the patency of the arterial system is crucial for the biliary system (1–4).

#### PRE- TRANSPLANTATION IMAGING

Imaging of the donor and recipient livers with advent of multislice techniques with submillimeter isotropic resolution usually relies on multiphase CT examination with quality arterial and portal venous phases for vascular structures. For a biliary anatomy MR (cholangiography) is of great value and is a method of choice for volumetric data and vasculature. Ultrasound is helpful to exclude diffuse and focal liver diseases in living donors and for the follow-up after removal of one of the liver lobes. Unfortunately, planning a liver transplantation to rely on ultrasound imaging alone is not possible. Combination of different imaging modality protocols before transplantation varies from center to center (1, 5).

Imaging procedures prior to transplantation must answer following questions:

- anatomic characteristics and measurements of the portal vein, hepatic veins and hepatic artery (in combination with CT and MRI);
- patency (thrombosis, external compression) of those vascular structures, proximity and involvement with tumors if any;
- presence, location and size of portosystemic collaterals in the recipient;
- presence of focal and diffuse liver disease in the donor liver;
- volumetric data.

#### POST- TRANSPLANTATION IMAGING

Post-transplantation imaging is primarily employed to evaluate the patency of the surgically created anastomoses between a donor liver and a recipient vasculature. Detailed description of the operation performed, preferentially with schematic drawings, makes the examination much faster and more reliable. In the early postoperative period Doppler ultrasound imaging is frequently performed as a bedside procedure once or two times a day. CTA is recommended within first week to assess vascular patency, nevertheless if Doppler ultrasound findings reveal suspected vascular complications CTA or/and conventional angiography with therapeutic procedures must be employed.

The most common vascular complications are stenosis and occlusion of the hepatic artery reported as high as 25–30% in living donor pediatric patients (7) however introduction of microsurgery techniques reduced the incidence below 5%. In adult cadaveric liver transplantation it varies from 1.5 to 9% (9).

Early occlusion results in loss of the transplant if revascularization procedures are not performed in time. Doppler ultrasound performed in asymptomatic post-transplant patients in first days after transplantation could detect hepatic artery thrombosis and save the transplanted liver. Failure to visualize transplanted artery in its usual course does not necessarily mean that the artery is occluded, because its

typical location could be significantly altered surgically. Visualization of normal flow in the intrahepatic branches may suggest that the common hepatic artery is patent, and attempt to trace it in retrograde fashion should be obtained. When the main artery is identified and confirmed to be patent, the region of the anastomosis should be investigated to rule out stenosis. Velocities higher than 200 cm/s are consistent with hemodynamically significant hepatic artery stenosis (3, 4). If there is a history of multiple anastomoses, all those areas should be meticulously examined. During the first days after transplantation the arterial waveform has usually high resistance, due to postoperative liver edema. At the end of the first week resistance gradually returns to normal values (3). Increase in HA resistance in late post-transplantation period may be caused by the rejection or due to recurrence of chronic liver disease. However those findings are unspecific and the diagnosis of rejection should rely on liver biopsy.

When the area of anastomosis is impossible to visualize and low resistance dampened poststenotic arterial waveform in intrahepatic branches is present, stenosis in the common hepatic artery must be suspected and angiography should be considered. Hepatofugal direction of the blood flow in some intrahepatic arteries may be observed as liver receives transcapsular collaterals from the diaphragmatic surface (10) in the presence of proximal artery occlusion.

Pseudoaneurysm of the hepatic artery is one of possible rare arterial complications and should be differentiated from the subhepatic

fluid collections. A-V fistulas and arteriobiliary fistula have been reported as anecdotal data in post-transplant patients (5).

Complications as thrombosis of the hepatic veins and IVC, stenosis of the anastomoses are very rare (9). Transplanted liver hepatic veins exhibit the same phasic flow characteristic of the normal liver. Loss of the phasicity and development of the continuous monophasic flow may be due to flow obstruction distally from the point of investigation, and anastomotic area downstream (proximal IVC anastomosis) should be examined by CT or MRI to rule out stenosis.

Bile duct patency is assessed by MR cholangiography and direct cholangiography procedures if ultrasound imaging is not informative. Intraoperative Doppler ultrasound is widely used in many medical centers to confirm patency of the arterial and venous anastomoses in the operating room. In living donors it is used to identify plane of resection, anatomic variations of the hepatic veins, hepatic artery and portal vein branching (11).

Evaluation of extrahepatic complications (hematomas, bilomas, abscesses etc.) should rely on cross-sectional imaging with CT or MRI depending on the preference of the imaging team, and ultrasound examination complementing as an excellent tool for continuous surveillance of the donated organ and image guided interventional procedures (1, 5).

**In conclusion**, the results of liver transplantation rely largely on the expertise of the imaging team to employ ultrasound imaging, CT, MRI and interventional angiography depending on the situation.

## REFERENCES

1. Tucker O, Heaton N, Zamboni GA, et al. Liver transplantation. In: *Imaging in transplantation*. Berlin, Heidelberg: Springer. 2007. p.99–137.
2. Tamosiunas AE, Labropoulos N. Evaluation of hepatoportal circulation. In: *Vascular diagnosis*. Elsevier Saunders. 2005. p.489–512.
3. Garcia-Criado A, Gilabert R, Nicolau C, et al. Early detection of hepatic artery thrombosis after liver transplantation by Doppler ultrasonography: prognostic implications. *J Ultrasound Med* 2001;20(1):51–8.
4. Dodd GD, Memel DS, Zajko AB, et al. Hepatic artery stenosis and thrombosis in transplant recipients: Doppler diagnosis with resistive index and systolic acceleration time. *Radiology* 1994;192(3):657–61.
5. Caiado AH, Blasbalg R, Marcelino AS, et al. Complications of liver transplantation: multimodality imaging approach. *Radiographics*. 2007;27(5):1401–17.
6. Bassignani MJ, Fulcher AS, Szucs RA, et al. Use of imaging for living donor liver transplantation. *Radiographics* 2001;21(1):39–52.

7. Samstein B, Emond J. Liver transplants from living related donors. *Ann Rev Med* 2001;52:147–60.
8. Trotter JF, Wachs M, Everson GT, Kam I. Adult-to-adult transplantation of the right hepatic lobe from a living donor. *N Engl J Med* 2002;346(14):1074–82.
9. Hellinger A, Roll C, Stracke A, et al. Impact of colour Doppler sonography on detection of thrombosis of the hepatic artery and the portal vein after liver transplantation. *Langenbecks Arch Chir* 1996;381(3):182–5.
10. Wachsberg RH, Bahramipour P, Sofocleous CT, Barone A. Hepatofugal flow in the portal venous system: pathophysiology, imaging findings, and diagnostic pitfalls. *Radiographics* 2002;22(1):123–40.
11. Fahy BN, Jarnagin WR. Evolving techniques in the treatment of liver colorectal metastases: role of laparoscopy, radiofrequency ablation, microwave coagulation, hepatic arterial chemotherapy, indications and contraindications for resection, role of transplantation, and timing of chemotherapy. *Surg Clin North Am* 2006;86(4):1005–22.

## Estonia-PACS – an integral part of the national e-Health Programme

M. Ulst<sup>1</sup>, A. Aavik<sup>1</sup>, A. Paats<sup>2</sup>, R. Käpp<sup>1</sup> –  
<sup>1</sup>Tartu University Hospital, <sup>2</sup>North-Estonia  
Medical Centre, Estonia

Recent developments of Estonia-PACS and integration with the national e-Health Programme are under discussion.

In 2006 two major Estonian hospitals, Tartu University Hospital and North Estonia Medical Centre, accomplished the creation of a country-wide picture archive (Estonia-PACS). The development process was started already in 2001 in Tartu, where a local mini-PACS was set up under the regional Baltic BITNET network programme. Further, the mini-PACS was expanded to meet the local and regional needs and now in 2008 approximately 88 per cent of radiological studies of Estonia are stored in Estonia-PACS. The capacity of the archive has reached 2.5 million studies, which means 118 TB of information (18 TB for quick access in cache and 2x50 TB in long-term mirrored storage – MAS). Approximately 150 GB of images are stored daily. Over 2700 registered users in all major hospitals and 98 per cent of general practitioners have authorised VPN-encrypted access to the images. Exponential growth of stored data is the major intimidating factor of PACS development. There are plans to store even new modalities (e.g. endoscopy, ECG). Hopefully, the capacity of the storage media will grow and

the cost per megabyte will continue to decrease as it did during the last decade. According to Estonian legislation it is mandatory to store clinical information over 30 years (in some cases 110 years). It is obvious that not all clinical information is worth long-term storing. Therefore the legislation should be revised to meet contemporary needs and possibilities.

During recent years PACS has tremendously changed the paradigms of medical informatics and has deep-rooted into the minds of medical users as something really valuable, accessible and reliable. Country-wide PACS has been the major accelerator of digitalisation of radiology departments. The benefits of digital images are so obvious that during a few years traditional analogue-film imaging-technologies have been disappeared from Estonian health care institutions. Even veterinarians prefer digital images. PACS has created the possibility to join the European teleradiology network and to export services. Many local county hospitals, unable to employ a 24h radiologist, buy diagnostic services via teleradiology from bigger centres. Teleradiology is the only chance for rural healthcare centres to maintain the diagnostic standards and to survive in the tough competition for patients.

The popularity of digital radiology in Estonia and the huge pool of end-users (over 2700) were the main factors, why the really existing and reliably working Estonia-PACS was automatically incorporated into the ambitious

national e-Health Programme supervised by the Ministry of Social Affairs and launched recently, in September 2008. Besides the PACS-module there are three other modules under development: the Health Information System (national archive of epicrisis), Digital Prescription System and Central Booking Desk. In the opinion of experts the last is the most critical and complicated part of the e-Health Programme. The ultimate goal is, that

the patient is able to compare the waiting lists of different medical institutions and to book online the visit to the desired specialist. Unfortunately, this task can not be accomplished online due to the diversity of hospital information systems. Nevertheless, the described national e-Health programme is designed over the 5-year period (2008–2013) which is sufficiently long time to overcome the obstacles or to change the scope.

## The measurements of the ophthalmic artery using MRI

**S. Rutkauskas, V. Gedrimas, V. Azelis** –  
Kaunas University Hospital, Lithuania

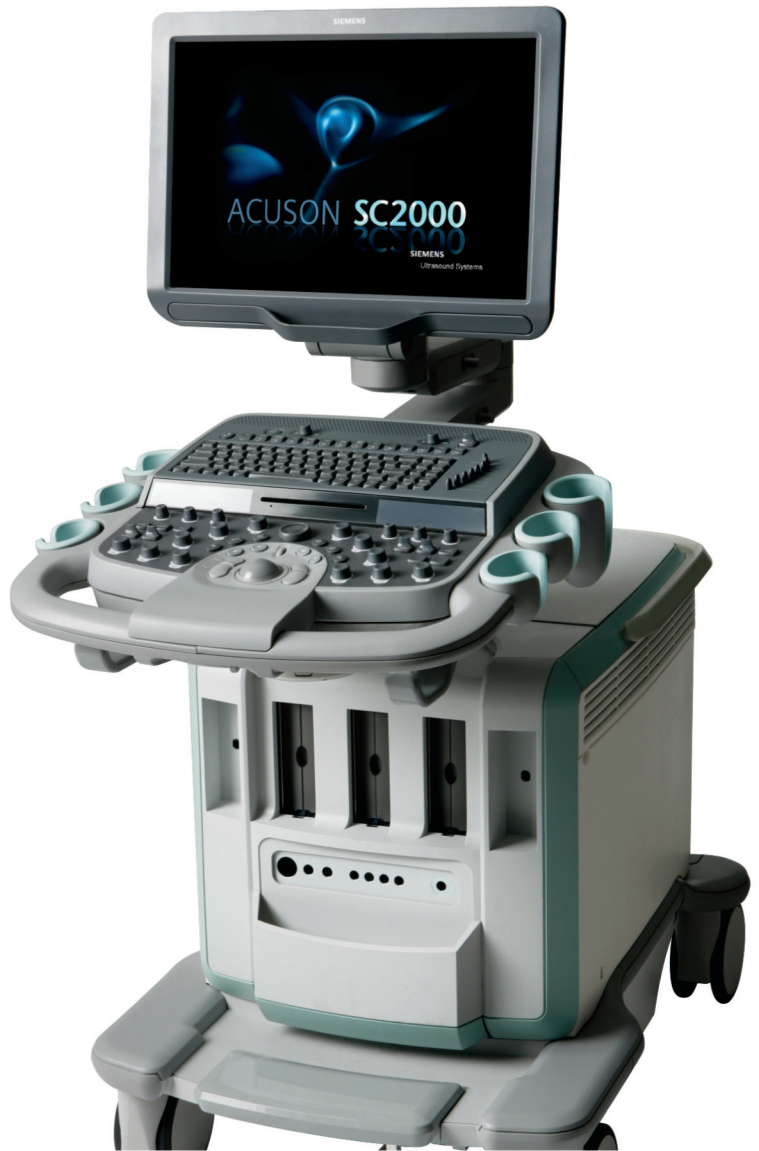The intracranial pressure influences the blood flow in different parts of the ophthalmic artery (OA). However, it is difficult to detect and to distinguish these intracranial (IC) and intracranial (ICr) parts using color Doppler ultrasonography. Magnetic resonance angiography (MRA) can help to visualize the variable course of OA main parts in different planes. Therefore our goal was to find the optimal angles for ultrasound transducer using MRA. 40 patients (mean age 48.4 years, range 16–78 years) were included in the study. The study comprised 11 men (mean age 49.5 years, range 24–70 years) and 29 women (mean age 48 years, range 16–78 years). The MRA investigations were performed in 2004–2005 by using a 1 T whole-body system (Gyrosan, NT). 100 sections were obtained with a three-dimensional time-of-flight technique (30/6.9; flip angle 20°; field of view, 220 mm; 100% RFOV; matrix size 512x512; two signals acquired; gap 0 mm; section thickness 0.6 mm with subsequent reconstruction of maximum intensity projections. The measurements were made using eFilm Workstation 2.1.2 (Merge eMed, 2006) program.

The middle line was drawn through the apex of the nose and the cerebral aqueduct in horizontal plane. Frankfurt line was drawn in the sagittal plane. Two additional lines were traced on both sides between the ultrasound transducer and the IC and ICr parts of OA. The angles between these lines, the middle and Frankfurt lines were measured. The imaginary point of transorbital ultrasound transducer was fixed 0.7 cm medially from the lateral upper margin of the orbit. All the results of continuous variables are expressed as means±SD. Comparisons were made by unpaired Student t test. All tests were used the 0.05 level of significance. All calculations were made with the STATISTICA for Windows statistical package version 5.0 (StatSoft, Inc 1995). The mean angle (36.9±2.7 degrees) was measured between the right ICr and middle lines in the horizontal plane (men 36.6±3.2, women 37.1±2.5, p>0.05), in sagittal plane 10.1±3.6 (men 12.4±3.4, women 9.1±3.2, p<0.05), in sagittal plane 9.3±3.7 (men 9.6±3.9, women 9.3±3.6, p>0.05). The angle between the right IC and middle lines in horizontal plane was 33.8±3.3 (men 32.6±3.8, women 33.9±3.0 p>0.05), in sagittal plane 4.8±3.8 (men 7.7±3.3, women 3.7±3.4, p<0.05), in sagittal plane 4.6±4.1 (men 6.1±3.9, women 4.0±4.0, p>0.05). During the transorbital

color Doppler ultrasonography, the transducer must be positioned in different way: 1) for both sexes (because the value of the both parts of right ophthalmic artery angles was significantly smaller for women then for men in sagittal plane), 2) for the intracanalicular parts of ophthalmic artery (because

the right intracanalicular angle was significantly larger then left in horizontal plane), 3) for the intracranial and intracanalicular parts of ophthalmic artery (because the value of the both intracranial angles was significantly larger then intracanalicular angles in horizontal and sagittal planes).





ACUSON SC2000 Uue põlvkonna ehhokardiograafia seade loob uued võimalused kaasaegses ehhokardioloogias.  
4Z1c Real-Time Volume Imaging Transducer

[www.siemens.com/healthcare](http://www.siemens.com/healthcare)

**SIEMENS**



