

Intra-articular injection of vitamin A: a rabbit model to study osteoarthritis

by *M.G. Grillo**^o, *G. Panzini***^o, *A. Di Virgilio***^o, *A. Corsi****, *M. Riminucci****, *P. Bianco****,
*L. Politi**, *R.N. Lorenzini***^o, *R. Scandurra**.

*Dipartimento di Scienze Biochimiche, Università di Roma "La Sapienza"

**Servizio Qualità e Sicurezza della Sperimentazione Animale, Istituto Superiore di Sanità, Roma.

***Dipartimento di Medicina Sperimentale e Patologia, Sezione di Anatomia Patologica, Università di Roma
"la Sapienza". ^o These authors have equally contributed to this work.

Summary

An experimental model of osteoarthritis (OA) induced by injection of vitamin A in knees of rabbits is presented. This model represents a modification and improvement of a preexisting one (*Boni et al., 1977; Benazzo et al., 1982*) based on a higher number of vitamin A injections. In our model, two vitamin A injections were sufficient to induce OA without exposure of the subchondral bone. The advantages of this model are: 1) the maintaining of articular cartilage could make the experimental joints suitable to test the reparative efficiency of candidate intra-articular pharmacological treatments, 2) animal stress and the risk of infections are strongly reduced in compliance with European legislation on laboratory animal welfare.

Introduction

Osteoarthritis (OA) represents one of the most frequent articular pathologies in humans, especially in adult and elderly individuals. With the progressive increase of life expectancy of Western populations, it represents a Public Health problem of increasing concern. From a clinical point of view, OA can be classified into acute, sub acute and chronic. Although the etiology of the various forms of OA is different, the pathogenesis is common and related to chondrocyte injury leading to a disturbance in the synthetic and degradative processes with the net result of accelerated cartilage matrix breakdown by chondrocytic enzymes (*Swiestra, 1983*). As a consequence, a vicious circle develops and leads to chondrocyte apoptosis and further degradation of the matrix and, in the most serious cases, to the complete loss of cartilage articular surface with exposure of the sub-chondral bone.

To date, anatomical and functional restoration of the integrity of the affected joints is not possible by local and/or systemic pharmacological treatments, but new surgical techniques, including autologous chondrocyte transplantation and osteochondral

auto-transplantation (*Chu et al., 1995; Gambardella, 1999*), are now being improved to heal chondral lesions. However, local intra-articular pharmacological treatments, mainly injection of drugs containing sodium hyaluronate (*Hamburger et al., 2003*) or glucosamine sulfate (*Lippiello et al., 2000*), have been demonstrated to protect the chondrocytes and reduce the extensive development radiological evolution of OA when some articular cartilage tissue is still preserved.

To test the reparative efficiency of new and alternative pharmacological treatments, it would be important to generate an animal model mimicking OA in humans in which different degrees of chondropathy can be reproduced. In order to obtain such a model, we have modified and simplified a previously published experimental model of OA in rabbits, in which intra-articular injections of vitamin A were used at different times and doses (*Boni et al., 1977; Benazzo et al., 1982; Lapadula et al., 1995*). We obtained OA after 2 injections and sacrifice of the animals 28 days after the second dose of the drug. In these animals, however, articular cartilage, which was never completely lost, could be responsive to

pharmacological treatments. In addition, the induction of OA after the administration of two injections of the drug has the significant advantage of reducing the animal stress and the risk of infection deriving from experimental procedures. Moreover this model reduces the suffering of the animals when compared to instability models of OA .

Materials and Methods

In this study 14 male New Zealand rabbits (Charles River Italy, Calco, Italy), weighing between 2.8 and 3.3 Kg, were used. The animals were housed and treated according to the European Directive 86/609/EEC. They were singly housed in steel wire bottomed cages, fed a rabbit standard pellet diet (Mucedola, Settimo Milanese, Italy) and given water *ad libitum*. The rabbits were anaesthetised with Ketamine 35mg/kg im (Ketavet, Farmaceutici Gellini, Aprilia Italy) and xylazine 5mg/kg im (Rompun, Bayer, Milano, Italy). After tricotomy, the right knees were infiltrated with 1 ml of liposoluble vitamin A (Arovite-Roche) at the same dose (300,000 I.U. in 1 ml of peanut oil containing alpha tocopherol 6.92 mg/ml) previously used by Benazzo et al. No alteration of the cartilage was induced in the left knees. Rabbits were divided into 7

groups (2 animals each) based on the number of intra-articular injection of vitamin A and time of sacrifice (table 1). The animals were sacrificed with an intravenous injection of mebenzonium iodide (Tanax) (Hoechst Roussel Vet, Milano, Italy); control and experimental knees were exposed through interior parapatellar incision, the patellar ligament was then incised and the capsulotomy was performed. After incision of the collateral and cruciate ligaments, the articular surface was exposed. Knees were removed by distal femur and proximal tibia osteotomies and immediately fixed in 4% formaldehyde (freshly made from paraformaldehyde) in 0.1M phosphate buffer pH7.2. After removal of the surrounding soft tissues, femur and tibia were separated. A 5 mm thick section was obtained from the external condyle and undecalcified for glycol-methacrylate (GMA) embedding as previously described (Bianco *et al.*, 1984). Five mm thick sections obtained from the intercondyloid fossa and the tibia plateau were decalcified in 10% EDTA in phosphate buffer at pH 7 and routinely embedded in paraffin. GMA sections were stained with May Grunwald-Giemsma (MGG); paraffin sections were stained with either haematoxylin and eosin or alcian blue.

Table 1. Time and number of intra-articular vitamin A injections.

GROUP	1	2	3	4	5	6	7
TIME (day)							
0	<i>FIRST vitamin A injection</i>						
7	Sacrifice						
12		Sacrifice	<i>SECOND vitamin A injection</i>				
19			Sacrifice	<i>THIRD vitamin A injection</i>			
26				Sacrifice			
33					Sacrifice		
40						Sacrifice	Sacrifice

Results

As previously described in diverse animal species (Boni *et al.*, 1977; Adams *et al.*, 1982; Benazzo *et al.*, 1982; Kimura *et al.*, 1994; Lapadula *et al.*, 1995), we were able to induce OA in the experimental knees of the rabbits by intra-articular injections of vitamin A. Gross changes of articular cartilage were not observed in the control knees, (fig

1A) nor in the experimental i.e. treated knees of the animals included in group 1 and 2 (fig 1B). In the experimental knees of the rabbits from group 3 to 5 the articular cartilage was less shiny than in the control knees and hyperemic areas were also detected (Fig 1C). Small abrasions on the surface of the articular cartilage of experimental knees of those rabbits in groups 6-7 and reduction in the

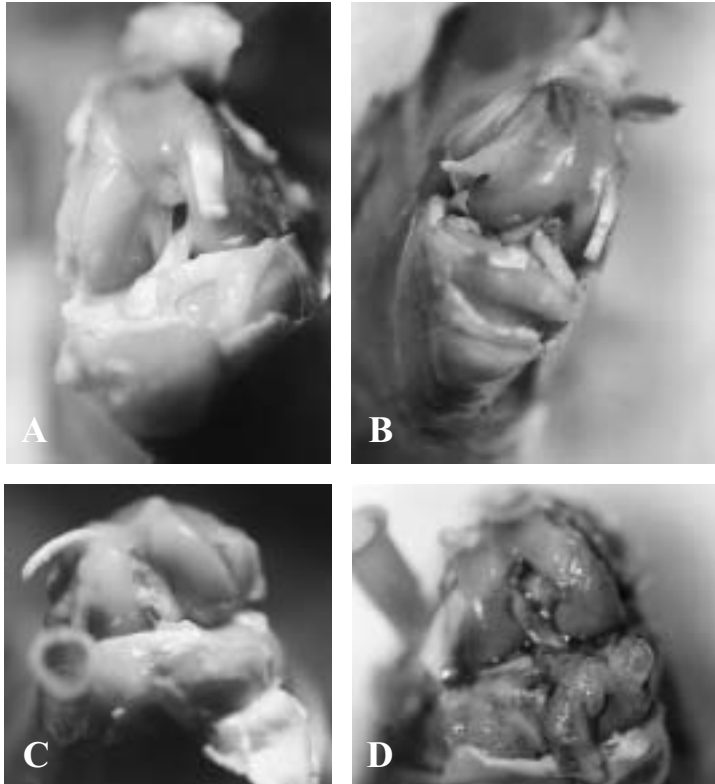


Figure 1. Macroscopic views of rabbit knees.

- (A) control knee: undamaged cartilage which appears shiny.
- (B) experimental knee of rabbit from group 2 at day 12 after the first vitamin A injection. The cartilage appears macroscopically less shiny.
- (C) experimental knee of rabbit from group 3 at day 7 after the second vitamin A injection. The cartilage appears less shiny macroscopically, and it is associated to hyperemic areas.
- (D) experimental knee of rabbit from group 7 at day 28 after the second vitamin A injection. The cartilage appears less shiny and less thick macroscopically; hyperemic and abrasion areas are also present.




Figure 2. Histology of articular cartilage of experimental (a-c) and control (d-f) knee of rabbit from group 3 at day 7 after the second vitamin A injection. Reduced staining of the extracellular cartilaginous matrix with alcian blue (b) and foamy appearance of chondrocyte for vacuolization of the cytoplasm (c) are evident at different degree.

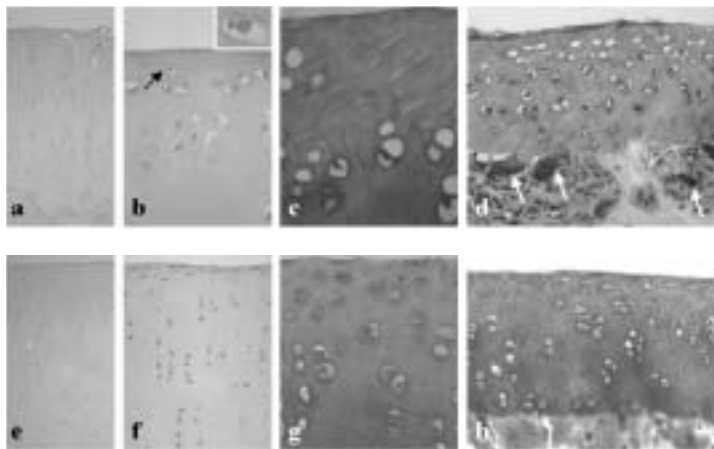


Figure 3. Articular cartilage of experimental (a-d) and control (e-h) knee of rabbit from group 7 at day 28 after the second vitamin A injection. In experimental knee (a), chondrocyte cellularity is not homogeneous for the occurrence of hypercellular and hypocellular areas, and articular surface is irregular as proved by the presence of partially detached portion of the cartilage matrix. Apoptotic bodies (arrow and inset in b) and empty lacunae (c, d), and osteoclasts (d, arrows) are evident in the more superficial area of articular cartilage and at the junction of cartilage with subchondral bone, respectively. All these changes were predominantly observed in the knees of the rabbits included in group 5, 6 and 7.

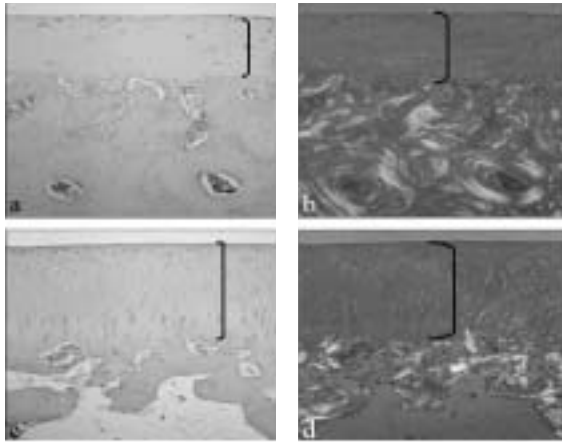


Figure 4. Transmitted (a, c) and polarized (b, d) light views of articular cartilage and adjacent subchondral bone of experimental (a, b) and control (c, d) knees of rabbit from group 7 at day 28 after the second vitamin A injection. Please note in experimental knee the reduction in the thickness of articular cartilage (a) and the subchondral new bone formation with well established Haversian systems (b). These changes were limited to the knee of the animals from groups 6 and 7.

thickness of articular cartilage were noted (fig 1D). Histological changes were detected in the experimental knees of the animals included in groups from 3 to 7 (Figures 2, 3 and 4). The absence of histological changes in the articular cartilage of the animals included in groups 1 and 2, accords well with previously published data by which, after one dose of vitamin A, morphological changes are evident only by ultrastructural analysis (*Lapadula et al., 1995*). As previously described (*Boni et al., 1977; Benazzo et al., 1982; Lapadula et al., 1995*), these changes consisted of a foamy appearance of the chondrocyte cytoplasm, reduction in proteoglycan content within the cartilage matrix (as proved by the reduced staining of the cartilage matrix with Alcian Blue), irregular cartilage surface, and variable chondrocyte density. Variability in chondrocyte density, with coexistence of hypercellular and hypocellular areas, was particularly pronounced in the knee of the rabbits in groups 5 to 7, in which intra-lacunar apoptotic bodies and many empty chondrocyte lacunae and osteoclasts were detected in the superficial articular cartilage layer and at the junction between articular cartilage and subchon-

dral bone, respectively. In the experimental knee of the animals included in the groups 6 and 7, areas of marked reduction in the thickness of the articular cartilage and focal new bone formation within the subchondral tissue were also observed.

Discussion

The aim of our study was to create a simple OA animal model, which may be useful to analyse the efficiency of pharmacological treatments, while previous studies (*Benazzo et al., 1982*) were aimed at studying the pathogenesis of vitamin A induced OA. Moreover our model, when compared to the instability OA model, greatly reduces the animal suffering according to Directive 86/609/EEC.

Based on our data, our model of OA in rabbits induced by intra-articular vitamin A injection is of some interest at least for two reasons. First, as demonstrated in the experimental knees of the rabbits included in group 3 and 7, it was possible to induce OA histological changes after two injections of Vitamin A, compared to previous work in which rabbits received more vitamin A injections (*Benazzo et al., 1982*). The reduction of injections represents a

significant advantage since it lowers both the animal stress, and the risk of infection deriving from experimental procedures. The comparison of morphological changes observed in the articular cartilage of the experimental knees of the animals included in group 3 (two injections and sacrifice 1 week after the second one), 6 (three injections and sacrifice three weeks after the last one), and 7 (two injections and sacrifice four weeks after the last one) indicates that the time of exposure to vitamin A, more than the number of doses, plays a critical role in determining the OA severity. As a matter of fact, the most severe histological changes, including significant reduction in articular cartilage thickness and focal subchondral new bone formation, were detected in the experimental knee from the animals included both in group 6 and 7, but not in group 3. Second, these changes, even when severe as in the knees of the animals included in group 6 and 7, did not include the complete loss of articular cartilage with exposure of the subchondral bone. The importance of maintaining cartilage tissue over subchondral bone has been proved to be a necessary condition for the local intra-articular pharmacological treatment of OA. Thus, our experimental model, by which marked OA without complete loss of the articular cartilage was induced in the knee of rabbits by intra-articular injections of two doses of vitamin A and sacrifice 4 weeks later, represents a reversible model of severe OA and offers the possibility to test the reparative efficiency of candidate pharmacological treatments.

Acknowledgements

The authors wish to thank Mr. Luciano Strangio for helping in carrying out the experimental procedures on rabbits.

References

- Adams ME & MEJ Billingham:* Animal models of degenerative joint disease. *Current topics of Pathology.* 1982, 71, 265-297.
- Benazzo F, G Cetta, E Finardi, A Parbellini, E Covoni & L Cecilian:* Artrosi Sperimentale da vitamina A nel coniglio e possibilità terapeutiche con acido ialuronico. *Giornale Italiano di Ortopedia.* 1982, 393-420.
- Bianco P, A Ponzi & E Bonucci:* Basic and "special" stains for plastic sections in bone marrow histopathology, with reference to May-Grunwald Giemsa and enzyme histochemistry. *Basic Appl Histochem.* 1984, 28, 265-279.
- Boni M, L Lenzi, P Berlanda, C Balduini, G Aureli, M Rizzotti & F Mascarello:* Experimental arthrosis from intraarticular vitamin A injection in the rabbit. Morphological and biochemical study. Consideration on the pathogenesis of human arthrosis in relation of the experimental model. *J.Orthop.Traumatol.* 1977, 3, 5-26.
- Chu CR, RD Coutts & MYoshioka:* Articular cartilage repair using allogenic perichondrocyte-seeded biodegradable porous polylactic acid (PLA): A tissue engineering study. *J. Biomed MaterRes.* 1995, 29, 1147-1154.
- Gambardella RA:* Autogenous osteochondral grafting: A multicenter review of clinical results, AANA, Vancouver, BC; Canada 1999
- Hamburger MI, S Lakhanpal, PA Moor & D Oster:* Intra-articular hyaluronans: A review of product-specific safety profiles. *Semin Arthritis Rheum.* 2003, 32, 296-309.
- Kimura Y:* Morphological changes in the knee joint of rat by intra-articular injection of vitamin A. *Nippon Seikeigeka Gakkai Zasshi* 1994, 68, 572-584.
- Lapadula G, B Nico, F P Cantatore, R La Canna, L Roncali & V Pipitone:* Early ultrastructural changes of articular cartilage and synovial membrane in experimental vitamin A-induced osteoarthritis. *Journal of Rheumatology.* 1995, 22, 1913-21.
- Lippiello L, J Woodward, R Karpman & TA Hammad:* In vivo chondroprotection and metabolic synergy of glucosamine and chondroitin sulfate. *Clin Orthop.* 2000, 381, 229-40.
- Swiestra BA:* Experimental arthrosis. Early changes in synovial morphology and lysosomal enzyme activities. *Acta Orthopedica Scandinavica,* 1983, 54, 317-321.