

# Spontaneous Congenital Hydrocephalus in Sprague Dawley Rat

by *Mohmad Sadik A. Mulla\*, Vinod Kumar Goyal, Santanu Jana & Ramakrishna Nirogi*

Discovery Toxicology, Suven Life Sciences Limited, Hyderabad, India

## Summary

Hydrocephalus is a neurological disorder that results from the accumulation of excess cerebrospinal fluid in the ventricles of the brain culminating in an enlarged cranium. This sporadic disorder may occur as a congenital malformation in many mammalian species including inbred rodent colonies at an early juvenile stage of life. Under conventional husbandry practice of breeding, 5 pups showing some clinical signs of neurological dysfunction at the age of 20 days were examined thoroughly. Detailed macroscopic examination demonstrated dome shaped head, thinned and deformed parietal bone, open/closed suture depending upon the severity of ventricular dilatation. Microscopic examination revealed dilated lateral ventricles, compressed and attenuated cortical mantle, spongy appearance of the sub-ventricular zone, stretched ventricular ependyma, flattened ependymal cell lining and infiltration of mononuclear cells in the ventricular lining.

## Introduction

Spontaneous developmental abnormalities of the central nervous system are extremely rare in rats. Congenital hydrocephalus occurs in 0.5 – 1.5 per 1000 births (*Somera, 2003*). It is a neurological disorder that results from the accumulation of excess cerebrospinal fluid (CSF) in the ventricles of brain which causes the cranium to become enlarged. This condition occurs sporadically in many mammalian species (*Hochbald, 1985; Szabo 1988; Wunschamann et al., 1981*) and has been observed in inbred rodent colonies within the first few weeks of life (*Kohn et al., 1977; Sasaki et al., 1983*). Most hydrocephalic pups die at 21-42 days however death was also observed within 2 weeks postpartum (*Kohn et al., 1977; Sasaki et al., 1983*).

Apparent causes of hydrocephalus include degenerative changes in the meninges, occlusion

of the aqueductal system, imbalance between production and absorption of CSF and disturbance of ciliary movement in the aqueduct (*John et al., 1991; Perez – Figares et al., 1998*). Incidences of congenital hydrocephalus have been reported in different mammalian species and strains however there is limited literature regarding spontaneously occurring hydrocephalus in Sprague Dawley rats. The present paper describes macroscopic and microscopic findings of hydrocephalus observed in a breeding colony of Sprague Dawley rats.

## Materials and Methods

Three male and two female pups from a single litter showed severe neurological clinical signs on day 20 post partum. This litter belonged to a small colony of breeding stock of 40 male and 80 female Sprague Dawley rats aged between 10-12 weeks, maintained under conventional husbandry practices; housed in solid bottom polycarbonate cages with paddy husk as bedding material. The animal room was maintained at  $21 \pm 3^{\circ}\text{C}$  temperature, 30-70% relative humidity, with 10-15 air changes per hour and an illumination cycle of 12 hours light and 12 hours dark. The five pups were moribund sacrificed using  $\text{CO}_2$  and detailed macroscopic examination was

\*Correspondence: Mohmad Sadik A. Mulla, Deputy General Manager

Discovery Toxicology, Suven Life Sciences Limited, Serene Chambers, Road-5, Avenue-7, Banjara Hills, Hyderabad, India 500034

Tel +91-40-23556039

Fax +91-40-23541152

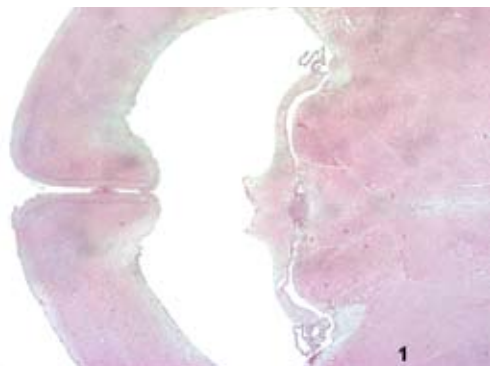E-mail msadik\_mulla@suven.com

performed. Brain was collected and fixed in 10% neutral buffered formalin and 4-5  $\mu$ m sections were stained with routine H&E staining for microscopic examination. Microscopic findings were graded as minimal, mild, moderate, marked and severe.

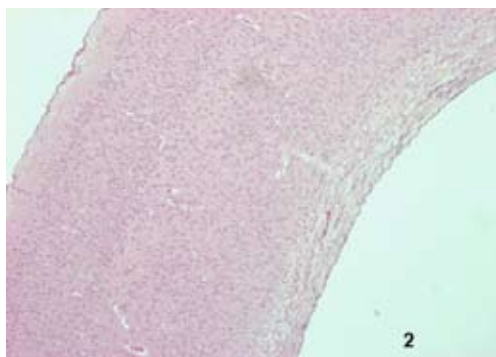
### Results

Clinical signs including tremor and dyspnea were observed in three male and two female pups 20 days after birth. Spastic paresis of hind limbs and absence of righting reflex were also recorded in two male pups. On macroscopic examination, dome shaped head was observed in all the pups. Reflection of skin revealed thinned and deformed parietal bones. Cranial sutures were open in two pups. Lateral ventricles were found to be filled with clear fluid and markedly dilated. No gross lesion was observed in other organs

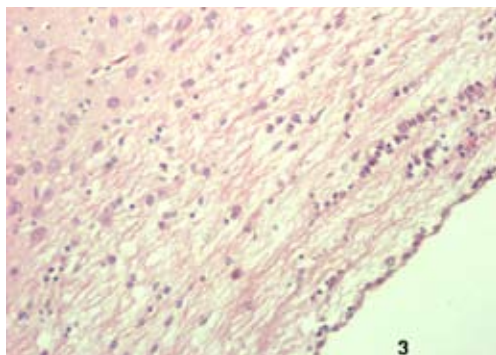
Microscopic examination of the brain revealed moderate to marked dilatation of lateral ventricles in all pups (Figure. 1) and the third ventricle only in one pup. Dilatation resulted in compression and attenuation of the cortical mantle (Figure. 2). Widening of intercellular spaces in the subventricular zone led to a spongy appearance, suggestive of white matter edema (Figure. 3). There was no evidence of stenosis of the aqueduct in any of the pups. Ependymal cells, lining the ventricles, appeared flattened like endothelial cells due to excess amount of fluid present in the



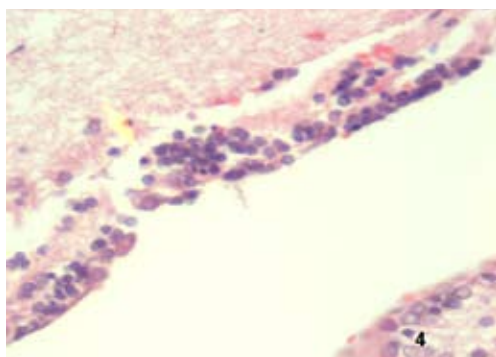
**Figure 1.** Brain; Rat Pup. Transverse section showing dilated lateral ventricles. **H&E X10.**



**Figure 2.** Brain; Rat Pup. Transverse section showing compressed cortical mantle. **H&E X40.**



**Figure 3.** Brain; Rat Pup. High power view of Fig. 2 showing subventricular spaces having spongy appearance. **H&E X100.**



**Figure 4.** Brain; Rat Pup. Ventricular lining showing infiltration of mononuclear cells. **H&E X400.**

ventricles in all pups. Further, there was infiltration of mononuclear cells at a few places (Figure. 4). Choroid plexuses appeared normal in most of the cases except congestion was observed in one pup. Mild to moderate meningeal congestion was also observed in all pups.

### Discussion

Incidences of congenital hydrocephalus were reported in various species like HTX rats, inbred mice and Golden hamsters (*Wunschamann et al., 1981; John et al., 1991; Nakamura and Sato, 1992; Perez – Figares et al., 1998; Edwards et al., 2006*). The present study revealed that pups survived for 20 days before moribund sacrifice, which was in concordance with the earlier reports in which pups having hydrocephalus generally do not survive long and die within 4 weeks (*Wada, 1998*). Long survival of rats suggests the possibility of a compensatory mechanism where acute hydrocephalus converts into compensatory or arrested hydrocephalus (*Wada, 1998*). Separation of skull sutures as observed grossly was probably the result of ventricular dilatation and elevated intracranial pressure (*Wada, 1998*). Other changes in the sub-ventricular zone (white matter edema and compression of cortical mantle) and ependymal lining of ventricle are in line with previous reports (*Szabo, 1988; Perez – Figares et al., 1998*). Stretching and compression of the sub-ventricular white matter was caused by expansion of the lateral ventricles; this has been substantiated by several recent studies where changes in ventricular volume were quantified and it was demonstrated that the lateral ventricle did expand relatively more than the third ventricle (*McAllister et al., 1998; McAllister et al., 2007*).

It is difficult to ascertain the precise mechanism of hydrocephalus in the present case. Pathogenesis of hydrocephalus is still not clear but some studies suggested the possibility of disturbed CSF circulation resulting from primary occlusion of the third ventricle during embryological development or aqueductal stenosis (*Sasaki et al., 1983*). Involvement of the subcommissural organ (SCO)

that has shown increased secretory activity in the pathogenesis of hydrocephalus has also been reported (*Perez – Figares et al., 1998; Somera, 2003*). Involvement of Mycoplasma was also reported in some of cases where there were pathological changes related to ciliated ependyma (*Kohn et al., 1977*). Lesions in the third ventricle and aqueduct can interfere with the ciliary propulsion of the CSF leading to accumulation of fluid. Hydrocephalus might also be associated with underdeveloped pia arachoid cells and poorly developed vein in the periosteal dural layer (*Kohn et al., 1981*). Though various mechanisms have been postulated, precise pathogenesis for hydrocephalus still remains to be elucidated.

### References

- Edwards JF, S Gebhardt- Henrich, K Fischer, A Hauzenberger, M Konar & A Steiger: Hereditary Hydrocephalus in Laboratory- reared Golden Hamsters (Mesocricetus auratus). Vet. Pathol. 2006, 43, 523-529.*
- Hochbald GM: Animal models of hydrocephalus: Recent developments. Proc. Soc. Exp. Biol. Med. 1985, 78, 1-11.*
- John PS, LW Barbar, CB Terrie, SB Kathy & B Roderick: Spontaneous Hydrocephalus in Inbred Strain of Mice. Jax Notes. 1991, 441.*
- Kohn DF, BE Kirk & SM Chou: Mycoplasma Induced Hydrocephalus in Rats and Hamsters. Infection and Immunity. 1977, 16 (2), 680-689.*
- Kohn DF, N Chinooskwong & SM Chou: Animal Model of Human Disease – Congenital Hydrocephalus. Am. J. Pathol. 1981, 114 (1), 184-185.*
- McAllister JP II, P Chovan, CP Steiner, MJ Johnson, MG Luciano, I Ayzman, AS Wood, JA Tkach, JF Hahn & MG Luciano: Differential ventricular expansion in hydrocephalus. Eur J Pediatr Surg. 1998, 8 (1 Suppl), 39–42.*
- McAllister JP II, RM Abdolvahabi, ML Walker, JA Mitchell & HC Jones: Effects of Congenital Hydrocephalus on the Hypothalamic Gonadotrophin-releasing Hormone System.*

Neurosurg Focus. 2007, 22 (4), 1-10.

*Nakamura Y & K Sato*: Role of disturbance of ependymal ciliary movement in development of hydrocephalus in rats. *Child Nervous System*. 1992, 8(1), 25-32.

*Perez – Figares, JM, AJ Jimenez, M Perez-Martin, P Fernandez-Llebrez, M Cifuentes, P Riera, S Rodriguez & EM Rodriguez*: Spontaneous congenital hydrocephalus in the mutant mouse hyp. Changes in the ventricular system and the subcommisural organ. *J. Neuropathol. Exp. Neurol.* 1998, 57(2), 188-202.

*Sasaki S, M Goto, H Nagano, K furuya, Y Omata, K Kanazawa*: Congenital hydrocephalus revealed in the inbred rat, LEW/Jms. *Neurosurgery*. 1983, 13 (5), 548-554.

*Somera, K*: Expression of nestin in H-Tx rats with inherited congenital hydrocephalus. *J. Undergraduate Res.* 2003, 7 (4).

*Szabo KT*: Congenital malformations in laboratory and farm animals. Academic press, Inc. San Diego, 1988.

*Wada M*: Congenital Hydrocephalus in HTX-rats: Incidence, Pathophysiology, and Developmental Impairment. *Neuro. Med. Chir. (Tokyo)*. 1988, 28, 955-964.

*Wunschamann A & M Oglesbee*: Periventricular Changes Associated with Spontaneous Canine Hydrocephalus. *Vet.Pathol.* 2001, 38, 67-73.