

# Apneic Oxygenation in Diagnosis and Treatment of Lung Tumours in an Experimental Porcine Model

by *B. Kjaergaard*<sup>1,\*</sup>, *P.R. Zepernick*<sup>1</sup>, *M.S. Nielsen*<sup>2</sup>, *H.K. Jensen*<sup>3</sup>, *D.T. Arp*<sup>2</sup>, *J.B. Thomsen*<sup>2</sup>,  
*J. Nielsen*<sup>2</sup>, *T. McCulloch*<sup>4</sup>, *J. Carl*<sup>2</sup>

<sup>1</sup>Department of Cardiothoracic Surgery, Center of Cardiovascular Research, Aalborg Hospital, Aarhus University Hospital, Denmark

<sup>2</sup>Department of Medical Physics, Oncology, Aalborg Hospital, Aarhus University Hospital, Denmark

<sup>3</sup>Department of Respiratory Diseases, Aalborg Hospital, Aarhus University Hospital, Denmark

<sup>4</sup>Department of Oncology, Aalborg Hospital, Aarhus University Hospital, Denmark

## Summary

**Objectives:** Respiratory movements may complicate diagnostic and therapeutic procedures such as biopsies and stereotactic irradiation therapy in lung cancer patients. An attempt to avoid respiratory movements, up to 30 minutes, long enough for procedures was performed in an animal study.

**Methods:** Ten anaesthetized minipigs ~30 kg were intubated in the trachea and small NiTi-stents were placed in various parts of the lungs. Using a muscle relaxing drug, the pigs were deprived of the ability to breathe for 30 minutes, a longer time than normally used for positioning and irradiation or for biopsies. No attempt to hyperventilate the animals was made prior to the apneic period. After a lung recruitment manoeuvre, a constant oxygen pressure of 20 cm water was applied to the airways. Using X-ray fluoroscopy, the position of the stents and thereby the movements of the lung, were monitored. Arterial gas analyses were performed every 5 minutes during the apneic period.

**Results:** All animals survived 30 minutes of apneic oxygenation. The median arterial oxygen partial pressure actually rose from 11.8 to 54.3 kPa and there were no changes in oxygen saturation. The median arterial carbon dioxide partial pressure rose from 6.9 to 18.7 kPa and the median pH fell from 7.41 to 7.04 during 30 minutes of apneic oxygenation. Our setup, or our strategy of anaesthesia, did not immobilise the internal parts of the lungs satisfactorily, and must be improved before it can be used in a clinical situation.

**Conclusion:** Physiologically, it is possible to stop respiration using apneic oxygenation for periods long enough to perform biopsies or stereotactic radiation therapy.

## Introduction

Radiation therapy plays an important role in the treatment of lung cancer, but a diagnosis is mandatory before treatment. Especially in stage I disease SBRT (stereotactic body radiation therapy) is an alternative treatment strategy for patients unfit for

surgery (Ricardi et al., 2010). Even elderly patients are reported to benefit from SBRT (*van der Voort van Zyp et al., 2010; Bayman et al., 2010*). New technologies with very high-dose stereotactic radiotherapy have been reported to be effective, but the challenge remains to avoid harmful radiation of surrounding normal lung tissue (*Lagerwaard et al., 2008; Onishi et al., 2007*). One method to spare surrounding normal tissue is to use respiration gated radiation therapy (RGRT) which typically irradiates the tumour during 30-40% of the respiratory cycle (*Haasbeek et al., 2009*). Better surgical methods with minimal invasive techniques

\*Correspondence: Benedict Kjaergaard

Department of Cardiothoracic Surgery, Aalborg Hospital, Postbox 365, Hobrovej 18-22, DK-9100 Aalborg, Denmark

Tel +45 99323648

Fax +45 99322425

E-mail benedict@dadlnet.dk

and improved anaesthesiology have provided more elderly and patients with concurrent diseases the possibility of surgery in countries with capacity to provide advanced hospitals. However in developing countries advanced lung surgery may be impossible and SBRT could be a realistic alternative to surgery for lung cancer treatment, but RGRT also demands expensive equipment. If it is possible to stop respiration during radiation therapy, this can theoretically improve the accuracy of the treatment in a simple and cheap way. Passive oxygenation of resting lungs, as an alternative to breathing, was suggested many years ago but the problem of removing carbon dioxide has been a limiting factor (*Kolobow et al., 1978*). New technologies have encouraged research in this area. When using an open lung approach with pure oxygen at a pressure of 20 cm H<sub>2</sub>O and CO<sub>2</sub>-elimination with a Novalung® device connected as a shunt between the femoral artery and the femoral vein it has been possible to ventilate pigs for many hours in an apneic way (*Lachmann, 1992; Nielsen et al., 2008*). For shorter periods of time, an open lung approach with pure oxygen but without CO<sub>2</sub>-elimination should be feasible. Our hypothesis was that it is possible to stop breathing in a safe way, using apneic oxygenation with a constant oxygen pressure in the airways for at least 20 minutes during stereotactic radiotherapy. In order to test this with a safety margin we planned the apneic oxygenation period to last 30 minutes under fluoroscopic supervision.

### **Material and Methods**

The study was approved by the Animal Experiments Inspectorate as a side experiment to another approved experiment using ten animals planned to be examined with bronchoscopy and x-ray before killing them.

Ten female Göttingen mini pigs ~ 30 kg (Ellegaard, Dalmose, Denmark) were used for the experiments. The animals were housed at 26 °C room temperature and fasted from the morning before anesthesia but they had access to water. They were anaesthetized with a mixture of two dissociative anaesthetics (Ketamin 6.25mg/ml and Tiletamin 6.25mg/ml), a

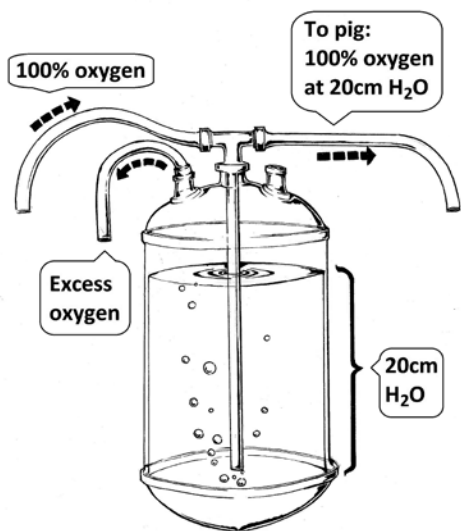
benzodiazepine (Zolazepam 6.25mg/ml), a synthetic opioid (Butorphanol 1.25mg/ml) and Xylazin (6.5mg/ml) an alpha 2 adrenergic agonist, which contains both sedative, hypnotic, analgesic and muscle relaxing properties. The anaesthesia was administered through successive intramuscular injections based on the clinical demand as reflected in haemodynamical changes and/or movement of the pig. The doses were 3.9 (3.1-5.7) ml/hour. Bradycardia was treated with intravenous Atropine ½ mg. The trachea was intubated with a 6.5 mm cuffed endotracheal tube (Portex Blue line, Smiths medical, UK) and the lungs were ventilated with a model 2000 ventilator (Halloweel Engineering & Manufacturing, MA, USA), using volume controlled positive pressure ventilation (PEEP: 5 cm H<sub>2</sub>O; V<sub>i</sub>: 8 mL/kg; respiratory frequency: 20/minute; inspiratory/expiratory ratio: 1:1). A catheter was inserted in the femoral artery for blood pressure monitoring and sampling of blood for analyses of pH, P<sub>a</sub>O<sub>2</sub>, P<sub>a</sub>CO<sub>2</sub>, and plasma-lactate (ABL 700, Radiometer, Copenhagen, Denmark). Continuous blood pressure and ECG were monitored using a Propaq 106® (Welch Allyn Protocol, Inc., Oregon, USA). A central vein catheter was inserted in a femoral vein for fluid and drug infusions. A bladder catheter was inserted.

When commencing the apneic oxygenation each animal received an intravenous injection of the non-depolarising muscle relaxing agent, Rocuronium, which was supplemented by additional doses if any movement was encountered. The demand for Rocuronium varied considerably: 141 (80-220) mg/hour. During the course of our experiment we decided to increase the administered amount to doses higher than recommended for human use, in order to avoid movement. Care was taken to ensure the pigs were under adequate anaesthesia before the use of Rocuronium, and during the use of Rocuronium extended attention was paid to the depth of anaesthesia especially to tachycardia.

Immobilisation of the animals was achieved with an individually adjusted vacuum pillow engulfing their backs and sides. The animals were protected against heat loss using blankets. Bronchoscopy was

performed under general anaesthesia through the tracheal tube using a paediatric video bronchoscope (BFP-180, Olympus Medical, Tokyo, Japan). After a complete inspection of the bronchial system, the bronchoscope was retracted and back loaded through the working channel with a catheter holding a thermo expandable NiTi-stent (Memocore®), Pnnmedical, Kvistgaard, Denmark). A second bronchoscopy was then performed with the stent mounted in front of the scope. A suitable bronchus was identified and the stent was expanded with warm water in accordance with the specifications of the thermo expandable material. When fixed it was released in sight of the bronchoscope and under fluoroscopic supervision one to four stents were placed in each animal. The Memocore stent and procedures have been described in detail in a previous paper (Carl *et al.*, 2011).

Before commencing apneic oxygenation a lung recruitment manoeuvre (forced deep inspirations at a very slow rate) was performed to minimize the risk of atelectasis after which the tracheal tube was connected to a pipe with pure oxygen delivered at a constant pressure of 20 cm H<sub>2</sub>O (Figure 1).



**Figure 1.** A simple system to control a constant oxygen pressure at 20 cm H<sub>2</sub>O

The internal stents were used in combination with an external marker (copper wire) on the skin to evaluate any movement within the lung during apneic ventilation. The relation between internal / external markers was measured on anterior – posterior (AP) plane by X-ray fluoroscopy images sequences taken over 2 minutes at the beginning of the apneic period and with ten minutes intervals until the end of the apneic ventilation. This resulted in 2000 images. The images were analyzed to find the maximal shift in position between internal / external markers in the frontal plane perpendicular to the AP axis. Conversion from pixels to mm was done using the part of the internal stent with a fixed diameter of 3.5 mm.

After the final measurements the animals were killed with an overdose of pentobarbital.

#### Statistics

The values presented in the Table are median and range. The curves presented in the Figures show all values with no calculations.

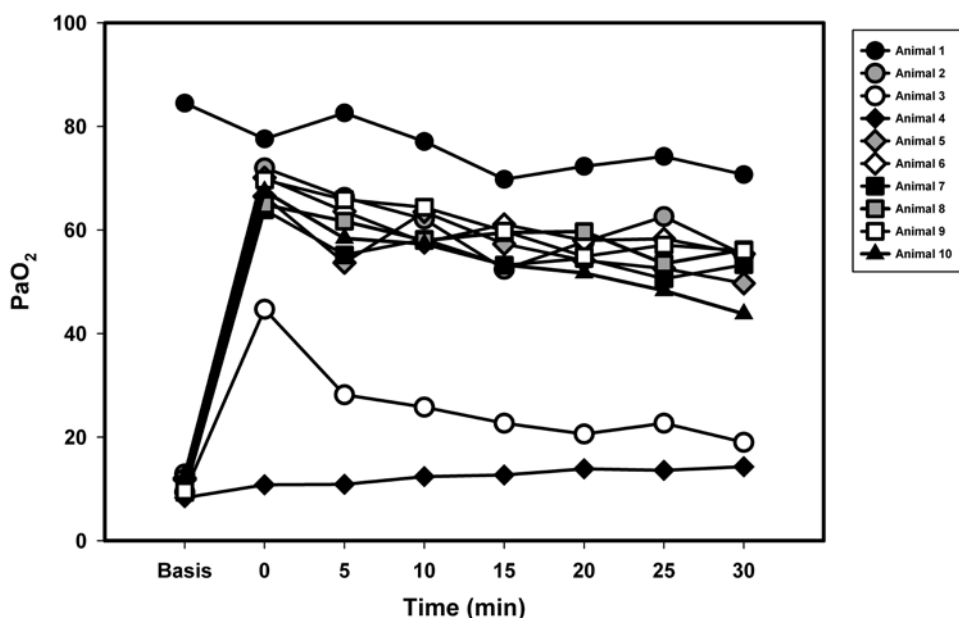
#### Results

All animals survived 30 minutes of apneic oxygenation. Vital signs and blood test results are presented in Table 1. Figure 2 shows the constant high arterial oxygen tension (PaO<sub>2</sub>) as a consequence of the uninterrupted oxygen supply to the lungs and Figure 3 shows the constant decreasing arterial pH during 30 minutes of apneic oxygenation as a consequence of the lack of CO<sub>2</sub> excretion. No severe cardiac arrhythmias were observed.

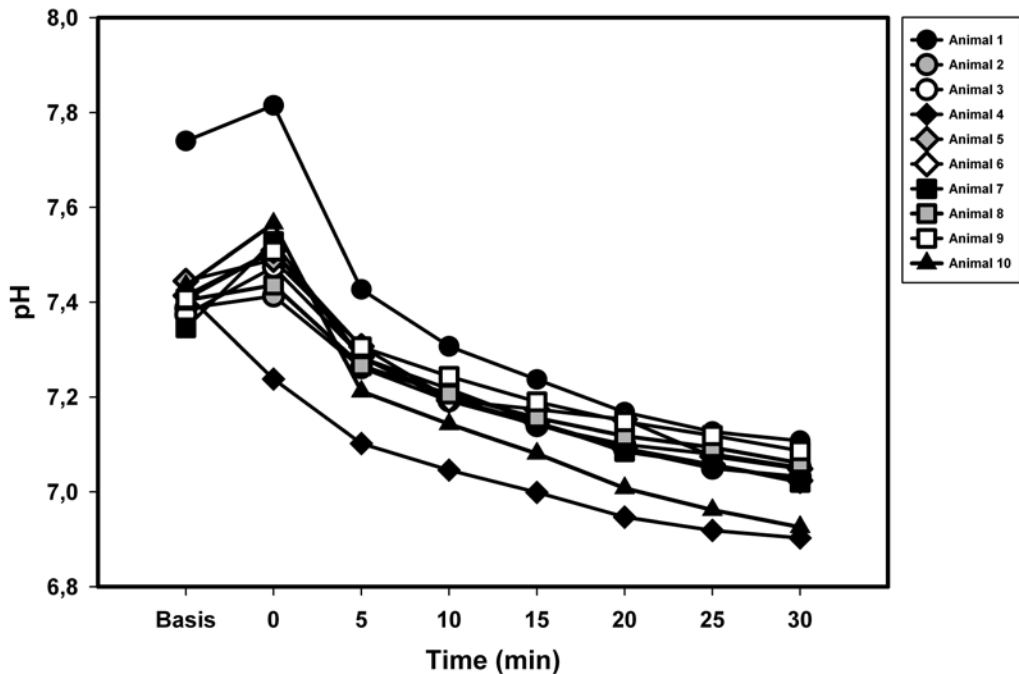
During the apneic period the lungs did move more than we expected, even though none of the pigs had visible respiratory movements. This shift of the stent position was intended to be almost zero. Shift in stent position was observed in all animals and in four animals a large a shift of more than 3 mm was observed (Figure 4). Large shifts were predominantly in the cranial-caudal direction. Small cyclic movements (less than 1 mm) in synchrony with heartbeat were observed for stent positioned close to the heart.

**Table 1.** Laboratory values before and after 30 minutes of apneic oxygenation  
All values are median and range

	Before apneic oxygenation	After 30 minutes of apneic oxygenation
Systolic BP (mm Hg)	110 (55-80)	158 (112-214)
Diastolic BP (mmHg)	80 (45-106)	111 (75-138)
Pulse (rate/minute)	69 (52-137)	81 (46-162)
PaO <sub>2</sub> (kPa)	11.8 (8.3-12.9)	54.3 (14.3-70.7)
PaCO <sub>2</sub> (kPa)	6.9 (2.8-7.9)	18.7 (15.8-29.3)
Arterial pH	7.41 (7.35-7.7)	7.04 (6.90-7.11)
Saturation (percentage)	1.00 (0.98-1.00)	1.00 (0.97-1.00)
Lactate mmol/l	2.1 (1.1-4.0)	2.9 (1.8-4.8)



**Figure 2.** PaO<sub>2</sub> (kPa) development during 30 minutes of apneic oxygenation. The first point Basis represents PaO<sub>2</sub> before recruitment manoeuvre and apneic oxygenation was started. Each animal is marked with a special sign.

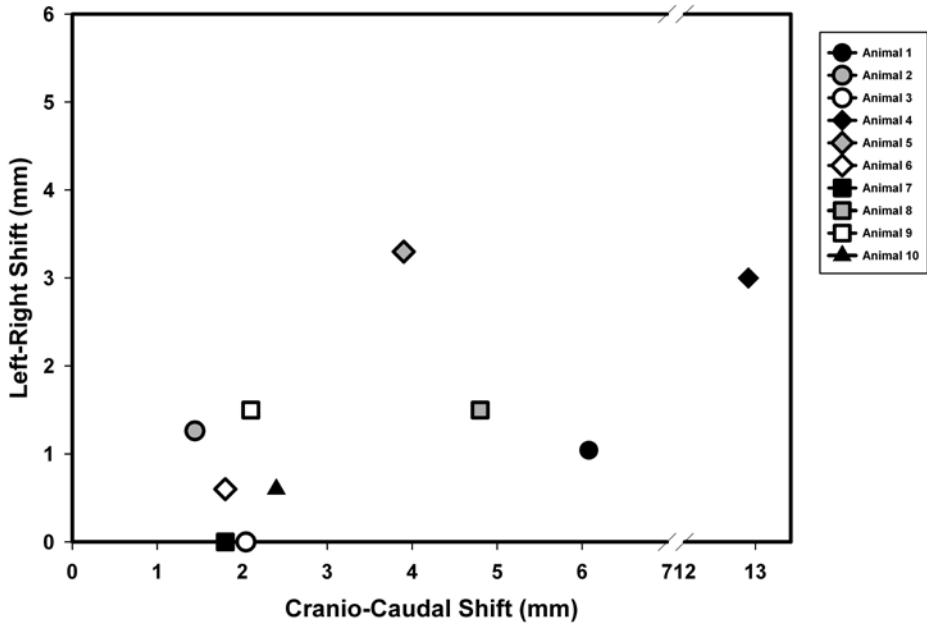


**Figure 3.** pH development during 30 minutes of apneic oxygenation. The first point Basis represents pH before recruitment manoeuvre and apneic oxygenation was started. Each animal is marked with a special sign.

### Discussion

We are convinced that no respiration took place, but in this setup we were not entirely satisfied with the immobilization of the lungs. The large shift in stent position may be explained by sudden expansions of smaller atelectasis even though we made an effort to avoid atelectasis by a lung recruitment manoeuvre before commencing apneic oxygenation. Other possible explanations may be inadequate relaxation or inadequate attachment of the animal to the stretcher. Especially pig no 4 seems to differ from the others, which may be a result of inadequate attachment. In a clinical situation it is important that the position of the radiated area does not move. Of course, small movements of the lungs due to pulsation of the heart and great arteries cannot be avoided, especially in areas close to the heart.

Equipment for RGRT is rather expensive and complicated; whereas apneic oxygenation is very cheap which makes it interesting as an option in radiation therapy for lung cancer and possibly other thoracic cancers if the methods can be improved. Normally, the time frame for radiotherapy is shorter than  $\frac{1}{2}$  hour, and during this period there were no oxygenation problems in our study, and the  $\text{CO}_2$  accumulation and accompanying pH fall were not of concern because normalization of these factors could be achieved with supplementary ventilation and expulsion of  $\text{CO}_2$ . We did not try to hyperventilate the animals before the apneic period which could have lowered the initial  $\text{CO}_2$  content thereby ultimately reducing the fall in pH. It may even be possible to treat a patient with sodium bicarbonate to adjust pH in case of problems during the relative short period of apneic oxygenation (*Buyssse et al.*



**Figure 4.** Unintended shifts of lung markers detected from X-ray fluoroscopy in the AP plane during 30 minutes of apneic oxygenation. Each animal is marked with a special sign.

2005). It is mandatory to use a pure oxygen supply to the airways, because nitrogen would accumulate in the alveoli and sooner or later result in a sudden fall in blood oxygenation (Nielsen *et al.*, 2010). A disadvantage is the need for general anaesthesia with relaxation and tracheal intubation to perform apneic oxygenation. This is especially true for the target group of patients who often have pulmonary co-morbidity and therefore have a greater risk of complications to general anaesthesia and ventilation itself (e.g. pneumonia).

The use of apneic oxygenation may also be beneficial in other clinical situations dealing with lung cancer, for instance in difficult Computerized Tomography (CT) guided biopsies or in CT guided local brachytherapy (Martinez-Monge *et al.*, 2008). In animal experiments, imaging techniques with CT scanners, Magnetic Resonance Imaging (MRI) and Positron Emission Tomography (PET) are often used in large animals during anaesthesia (Alstrup

and Winterdahl, 2009). When exact coordinates in the thoracic organs are desirable for these examinations we find apneic oxygenation an easy way to control organ positions during the procedures. The use of apneic oxygenation demands minimal equipment.

The study has some limitations: the species difference from humans and the use of healthy pigs. The monitoring of the animals was different to that in humans. Even though the animals were insulated with blankets to minimise temperature loss it would have been appropriate to measure temperature, for example using a bladder temperature gauge because hypothermia could influence oxygen demand and carbon dioxide production. In future animal experiments, we will recommend improvements in the setup with continuous and controllable intravenous dosing of medications that can be used for humans, so a possible influence of the medications on metabolism in humans can be determined. It would also

enhance the experiments if the pigs were allowed to survive for some days to test possible side effects of apneic oxygenation.

Movement in the AP direction was not detected, which means any movement observed may in fact be even larger than measured. The medications for relaxation may be less effective in pigs than in humans. There were remarkable differences in the need for Rocuronium among the pigs. The medication strategy in humans must be more sophisticated.

Even though the theory works in this setting the results cannot be translated to the patient population who would be treated with RGRT. Some of these patients suffer marginal lung function with elevated levels of CO<sub>2</sub>. Treatment with apneic oxygenation cannot be done without general anaesthesia so it can hardly be on an ambulatory (outpatient) basis.

The patient described in the text box had the benefit of apneic oxygenation.

### Conclusion

Apneic oxygenation may be an option in stereotactic radiotherapy as a cheaper method than RGRT. In an animal model it is possible to control oxygenation and CO<sub>2</sub> content for at least ½ hour on the radiation stretcher with simple equipment. Better control of the position of the tumour must be achieved than was the case in this study and the method needs improvement before it can be used for humans.

### Acknowledgements

We thank Pnnmedical, Kvistgaard, Denmark for delivering NiTi stents and for economic support to the trial

### Text box with patient case

Patient case: example of the benefit of apneic oxygenation

A 70-year old woman suffering severe chronic obstructive pulmonary disease was suspected for a small lung cancer, suitable for stereotactic body radiation therapy (SBRT). CT guided biopsy of the tumour failed due to respiratory movements and the patient developed a life threatening pneumothorax.

After pleural drainage a successful attempt was made to obtain a biopsy of the cancer during muscle relaxant anaesthesia with pure oxygen supply under 15 cm water pressure in a cuffed tracheal tube for 13 minutes. During this period no respiratory movement took place. Her oxygen saturation did not fall below 99%, arterial CO<sub>2</sub> increased from 5 to 9 kPa with a pH fall to 7.2. The diagnosis was lung cancer, and she was treated with SBRT afterwards.

### References

- Alstrup, A. K. O. and M. Winterdahl*: Imaging techniques in large animals. *Scand.J.Lab. Anim. Sci.* 2009, 36, 55-66.
- Bayman, N., N. Alam and C. Faivre-Finn*: Radiotherapy for lung cancer in the elderly. *Lung Cancer* 2010, 68, 129-36.
- Buyse, C. M., J. C. de Jongste and Hoog M. de*: Life-threatening asthma in children: treatment with sodium bicarbonate reduces PCO<sub>2</sub>. *Chest* 2005, 866-70.
- Carl, J., H. K Jensen, J. Nielsen, Nielsen.M.S., M. Schmidt, and Loeschke S*: A new fiducial marker for gated radiotherapy in the lung. A feasibility study of bronchoscopy based insertion and removal in Göttingen mini pigs. *Scand.J.Lab. Anim.Sci.* In press.
- Haasbeek, C. J., B. J. Slotman and S. Senan*. Radiotherapy for lung cancer: clinical impact of recent technical advances 6. *Lung Cancer* 2009, 64,1-8.
- Kolobow, T., L. Gattinoni, T. Tomlinson and J. E. Pierce*: An alternative to breathing. *J.Thorac. Cardiovasc.Surg.* 1978, 75, 261-6.
- Lachmann, B*: Open up the lung and keep the lung open. *Intensive Care Med.* 1992, 18,319-21.
- Lagerwaard, F. J., C. J. Haasbeek, E. F. Smit, B. J. Slotman and S. Senan*: Outcomes of risk-adapted fractionated stereotactic radiotherapy for stage I non-small-cell lung cancer. *Int.J.Radiat. Oncol.Biol.Phys.* 2008, 70, 685-92.
- Martinez-Monge, R., M. Pagola, I. Vivas and J. M. Lopez-Picazo*: CT-guided permanent brachytherapy for patients with medically inoper-

- able early-stage non-small cell lung cancer (NSCLC). *Lung Cancer* 2008, *61*,209-13.
- Nielsen, N. D., G. Andersen, B. Kjaergaard, M. E. Staerkind and A. Larsson*: Alveolar accumulation/concentration of nitrogen during apneic oxygenation with arteriovenous carbon dioxide removal. *ASAIO J.* 2010, *56*,30-4.
- Nielsen, N. D., B. Kjaergaard, J. Koefoed-Nielsen, C. O. Steensen and A. Larsson*: Apneic oxygenation combined with extracorporeal arteriovenous carbon dioxide removal provides sufficient gas exchange in experimental lung injury. *ASAIO J.* 2008, *54*,401-5.
- Onishi, H., H. Shirato, Y. Nagata, M. Hiraoka, M. Fujino, K. Gomi, Y. Niibe, K. Karasawa, K. Hayakawa, Y. Takai, T. Kimura, A. Takeda, A. Ouchi, M. Hareyama, M. Kokubo, R. Hara, J. Itami, K. Yamada, and T. Araki*: Hypofractionated stereotactic radiotherapy (HypoFXSRT) for stage I non-small cell lung cancer: updated results of 257 patients in a Japanese multi-institutional study. *J Thorac.Oncol.* 2007, *2*, S94-100.
- Ricardi, U., A. R. Filippi, A. Guarneri, F. R. Giglioli, P. Ciammella, P. Franco, C. Mantovani, P. Borasio, G. V. Scagliotti and R. Ragona*: Stereotactic body radiation therapy for early stage non-small cell lung cancer: results of a prospective trial. *Lung Cancer.* 2010, *68*, 72-7.
- van der Voort van Zyp NC, Holt B. van der, R. J. van Klaveren, P. Pattynama, A. Maat, and J. J. Nuyttens*: Stereotactic body radiotherapy using real-time tumor tracking in octogenarians with non-small cell lung cancer. *Lung Cancer.* 2010, *69*, 296-301.