

Case report: Spontaneous staphylococcal arthritis in athymic SPF mice

by M. Wullenweber¹⁾, F. Deerberg¹⁾, W. Lenz²⁾ & G. O. Adegoke³⁾

¹⁾ Central Institute for Laboratory Animal Breeding, POB 910345, D 3000 Hannover 91, FRG.

²⁾ Institute of Medical Microbiology and Immunology, University of Bonn, D 5300 Bonn, FRG.

³⁾ Department of Food Technology, University of Ibadan, Ibadan, Nigeria.

Staphylococcus aureus is a well-known pathogen of laboratory animal stocks. It is responsible for abscess formation in the subcutis, as well as in several other organs and tissues, furthermore for exudative dermatitis and mastitis particularly in mice (McBride *et al.* 1981, Wullenweber-Schmidt *et al.* 1987). A literature search in relevant data banks, covering the last decade, did not give any information on cases of *S. aureus*-mediated spontaneous septic arthritis in mice. The present paper describes six cases of natural purulent arthritis in our Han:NMRI-nu/nu mouse stock.

CLINICAL HISTORY

Six, 5 week-old, male Han:NMRI-nu/nu mice probably derived from the same litter were sent to our diagnostic service for further investigation. The mice showed remarkably swollen hock joints of both hind legs (Fig. 1) but no subcutaneous abscesses or other pathological alterations. Incision of the joints under aseptic conditions liberated abundant yellowish pus.

PATHOLOGY

Necropsy of the mice did not show any purulent process in their internal organs. Hi-

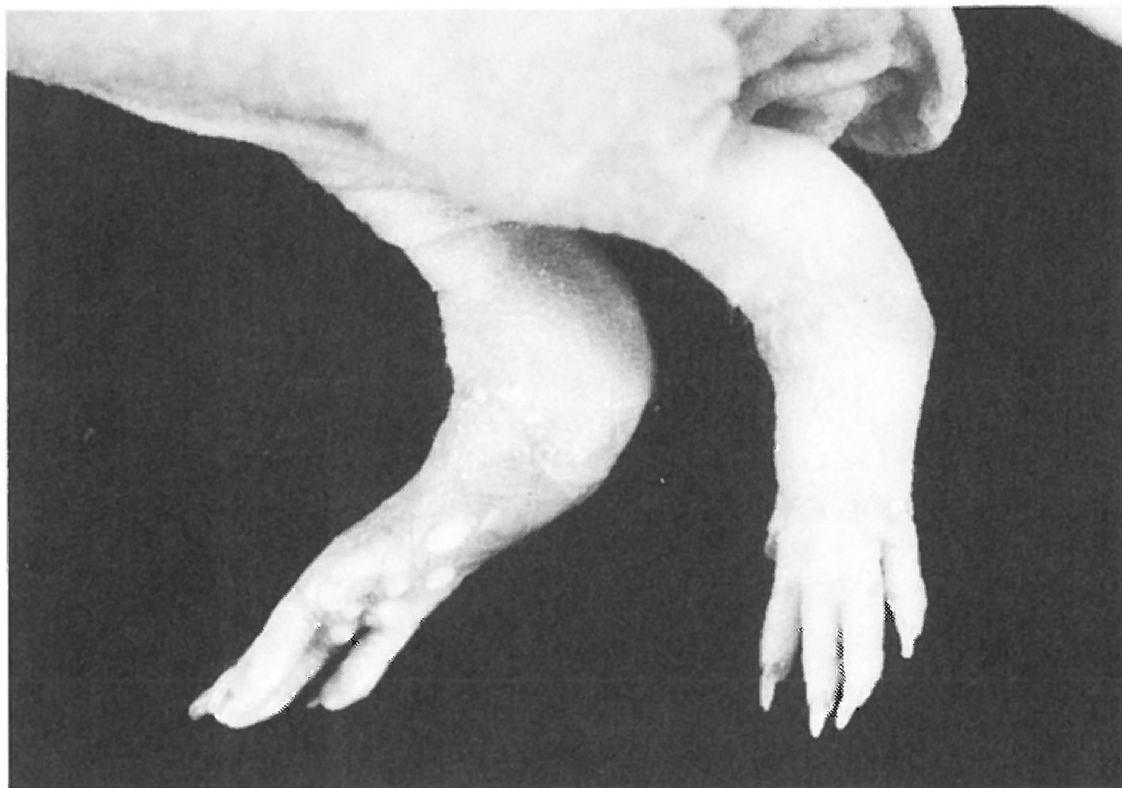


Fig. 1. NMRI-nu/nu mouse with swollen hock joints caused by purulent arthritis.

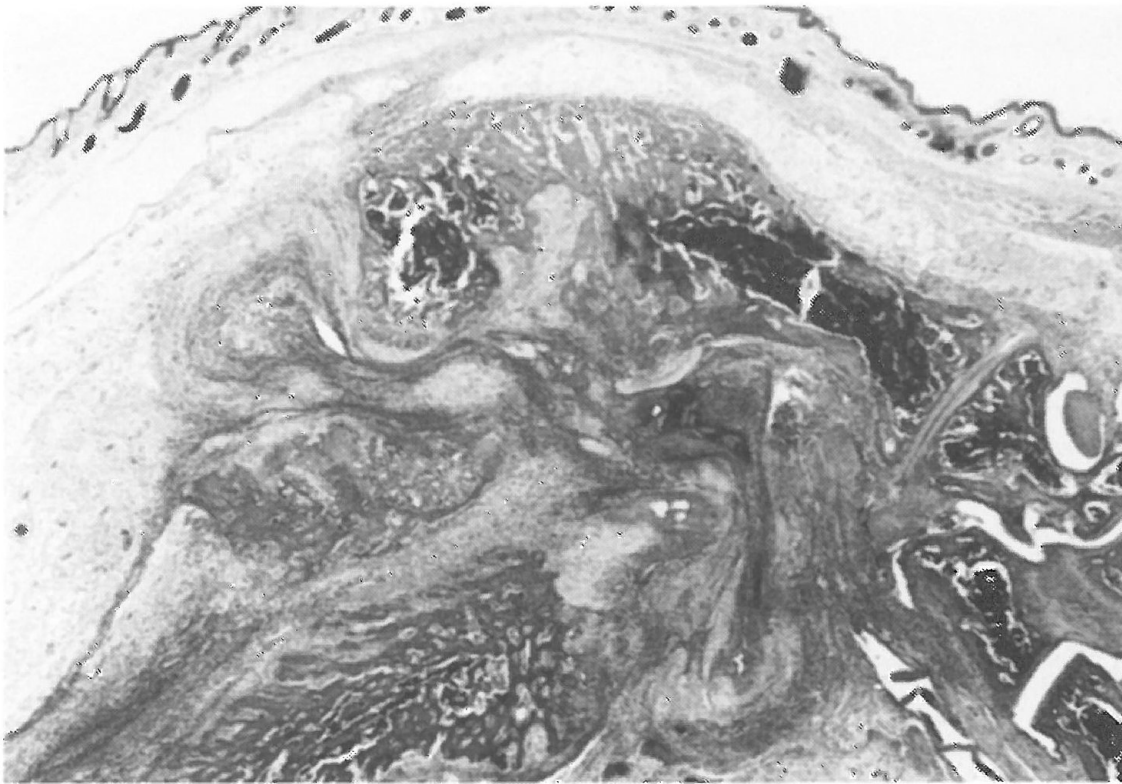

Fig. 2. Hock joint with peri- and intraarticular proliferation of fibrous tissue and purulent infiltration. H.E., $\times 14$.

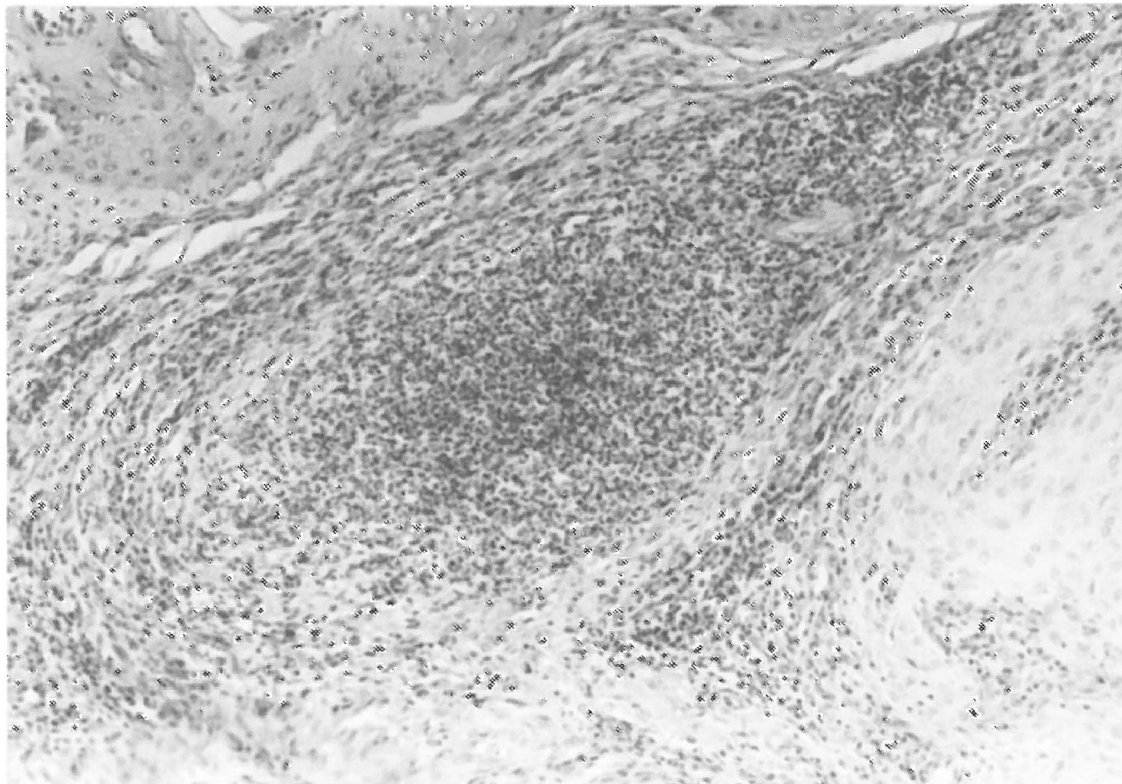


Fig. 3. Microabscess in the periarticular fibrous tissue. H.E., $\times 144$.

stological examination of the hock joints showed the typical features of purulent arthritis. Joints and hock bones were found in an abundant amount of fibrous tissue (Fig. 2) infiltrated by large numbers of neutrophils, mononuclear leucocytes and occasional macrophages. In nearly all the altered joints microabscesses could be demonstrated in the hyperplastic peri- and intra-articular stromal connective tissue (Fig. 3). In several localizations the infection had spread across the articular cartilage causing degeneration and destruction of the cartilage and severe purulent osteomyelitis.

BACTERIOLOGY

The barrier-maintained Han:NMRI-nu/nu breeding stock is routinely monitored and found to be free of murine viral or mycoplasmal infections. The only bacterial pathogen routinely isolated from the mouse colony was an enzootically spread strain of *Staphylococcus aureus*. This strain was responsible for cutaneous abscess formation and occasional cases of dermatitis and mastitis. Gram-stained smears of the pus showed Gram-positive cocci. Further bacteriological examinations, using standard methods (coagulase tube test, Voges Proskauer reaction, acid from mannitol), showed a protein A-positive *S. aureus* strain which when phage-typed, using the International set of phages, gave 3A/3C (\pm 55/71) at 100 \times RTD (Routine Test Dilution).

DISCUSSION

In humans, purulent arthritis is caused by different bacterial species amongst which *S. aureus* dominates, especially in children older than 2 years, in succession of an osteomyelitis and occasionally after septicaemia (Meyer 1984). Predisposing factors in human septic arthritis include extra-articular infection, arthritis in the infected joint, antibiotic treatment, serious chronic illness and immunosuppressive therapy (Goldenberg & Cohen 1976).

The NMRI-nu/nu mouse is athymic and

therefore can be regarded as immunodeficient. This condition can be assumed as one predisposing factor in the development of the arthritis due to *S. aureus*. Moreover, the age of the mice (5 weeks) can be regarded as a further predisposing factor when it is realised that domestic animals like turkeys (Nairn 1973), pigs (Hummel 1974) and poultry (Blobel & Brückler 1984) are known to develop staphylococcal synovitis, arthritis and periartthritis in their first weeks of life. Furthermore, Nairn (1973) observed that susceptibility to staphylococcal infection of the joints in turkeys decreases at the time the growth of the hollow bones ceases. Another reason for the occurrence of arthritis in the six mice could be a genetic susceptibility to this disease.

It is known that *S. aureus* strains of the phage complex 3A/3C/55/71 are spread among NMRI and NMRI-nu/nu mice in the SPF house where the arthritis cases were observed. These particular *S. aureus* strains cause cutaneous abscesses and mastitis (Wullenweber *et al.* 1990). Apart from the cases described herein, no further staphylococcal arthritis could be recorded. Even after the stringent conditions of an intravenous application of *S. aureus* phage type 3A/3C/55/71 into NMRI and NMRI-nu/nu mice no formation of arthritis could be seen (Wullenweber-Schmidt *et al.* 1988).

Devriese (personal communication) found that the strain of *S. aureus* isolated from the mice under study was of crystal violet type A and beta-haemolysin negative. This strain is however different from the *S. aureus* strain of the same phage type which caused high mortality in a rabbitry among newborn and very young animals mostly due to exudative dermatitis (Okerman *et al.* 1984).

Summary

Six cases of spontaneous purulent arthritis confined to the hock joints in male Han-NMRI-nu/nu mice have been observed in a SPF colony. Bacteriological examination revealed a protein A-positive *Staphylococcus aureus* belonging to phage group II. results of the histological, bacteriological

examinations and the importance of *S. aureus* of the 3A/3C/55/71 phage complex for small laboratory animal are discussed.

Resumé

I en SPF koloni af han NMRI-nu/nu mus blev observeret purulent haselbetsbetændelse hos 6 haner. Bakteriologiske undersøgelser afslørede tilstedeværelse af *Staphylococcus aureus* tilhørende fag-gruppe II. Resultaterne af de histologiske og bakteriologiske undersøgelser samt betydningen af *S. aureus* tilhørende fag-komplekset 3A/3C/55/71 for mindre forsøgsdyr bliver diskuteret.

Yhtenveeto / K. Pelkonen

SPF-koloniassa esiintyi äkillisesti kuudessa Han:NMRI-nu/nu hiiressä märkivä kinnerniveltulehdus. Bakteriologisesti voitiin osoittaa A-proteiinipositiivinen faagiryhmä II:een kuuluva *Staphylococcus aureus*. Artikkelissa pohditaan saatuja histologisia ja bakteriologisia tuloksia ja *S. aureuksen* (3A/3C/55/71 phage complex) merkitystä pienten koe-eläinten terveydelle.

References

- Blobel, H. & Brückler, J.*: Staphylococcal diseases in animals. In *Staphylokokken und Staphylokokken-Erkrankungen* (ed. W. Meyer), pp. 405–419. Jena: VEB Gustav Fischer Verlag 1984.
- Goldenberg, D. L. & Cohen, A. S.*: Acute infectious arthritis. A review of patients with non-gonococcal joint infections (with emphasis on therapy and prognosis). *The American Journal of Medicine* 1976, 60, 369–377.
- Hummel, R.*: Epizootology of staphylococci, and some remarks on the pathogenesis of staphylococcal infections in animals. In *Staphylokokken und Staphylokokken-Erkrankungen* (ed. W. Meyer), pp. 485–499. Jena: VEB Gustav Fischer Verlag 1984.
- McBride, D. F., Starck, D. M. & Walberg, J. A.*: An outbreak of staphylococcal furunculosis in nude mice. *Laboratory Animal Science* 1981, 31, 270–272.
- Meyer, W.*: Staphylokokken als Krankheitserreger bei Mensch und Tier. In *Staphylokokken und Staphylokokken-Erkrankungen* (ed. W. Meyer), pp. 333–398. Jena: VEB Gustav Fischer Verlag 1984.
- Nairn, M. E.*: Bacterial osteomyelitis and synovitis of the turkey. *Avian Disease* 1973, 17, 504–517.
- Okerman, L., Devriese, L. A., Maertens, L., Okerman, F. & Godard, C.*: Cutaneous staphylococcosis in rabbits. *The Veterinary Record* 1984, 114, 313–315.
- Wullenweber-Schmidt, M., Jonas, C., Werhan, K. & Brönnemann, K.*: Distribution of *Staphylococcus* species in barrier-maintained colonies of mice and rats and their caretakers. *Zeitschrift für Versuchstierkunde* 1987, 30, 85–93.
- Wullenweber-Schmidt, M., Kaspereit-Rittinghausen, J. & Jonas, C.*: Pathogenicity of *Staphylococcus aureus* phage type 3A/3C/55/71 and *Staphylococcus sciuri* in germfree euthymic mice after intravenous infection. *Scandinavian Journal of Laboratory Animal Science* 1988, 15, 97–105.
- Wullenweber, M., Lenz, W. & Werhan, K.*: *Staphylococcus aureus* phagetypes in barrier-maintained colonies of SPF mice and rats. *Zeitschrift für Versuchstierkunde* 1990, 33, 57–61.