

Two Cases of unusual Localization of Granular Cell Tumour in Wistar Rats.

by *I. Thorup* and *E. Kristiansen*, Institute of Toxicology, National Food Agency of Denmark, 19, Mørkhøj Bygade, DK-2860 Søborg, Denmark

Spontaneously occurring granular cell tumours in the rat are mostly seen in the brain and meninges (Maekawa et al. 1984, Mitsumori et al. 1987). Only a few other sites are reported, namely the retroperitoneal cavity, pituitary gland and trigeminal nerve (Mitsumori et al. 1987). In the present cases the tumours were localized in the muscle of the thigh and in the axilla respectively and hence different from that normally seen in rats. On the other hand both tumours were found at places similar to that reported in humans (Morrison et al. 1987, Robbins 1967). Both cases were found in a lifespan carcinogenicity study.

Case 1: A 30-month-old, female Wistar rat. At autopsy, a light yellow, homogeneous tumour, measured 6 mm in diameter was found superficial in the right thigh on a level with trochanter

major. Histologically the tumour consisted of large polygonal cells with abundant pink granular and vacuolated (foamy) cytoplasm. The nuclei were round and light with prominent nucleoli. Mitotic figures were not observed. Between the cells a delicate collagenous network was seen. The tumour cells spread apart the individual muscle cells and isolated muscle fibers were seen in the tumour mass. The cytoplasm of the tumour cells revealed large quantities of PAS-positive granules, which were resistant to diastase treatment. The cytoplasmic granules did not stain metachromatic with toluidine blue. Cross-striation, which could indicate a myogenic origin, was not observed in a phosphotungstic acid-hematoxylin (PTAH) stain. S-100 nerve protein, which could indicate a neural origin, was not demonstrated by im-

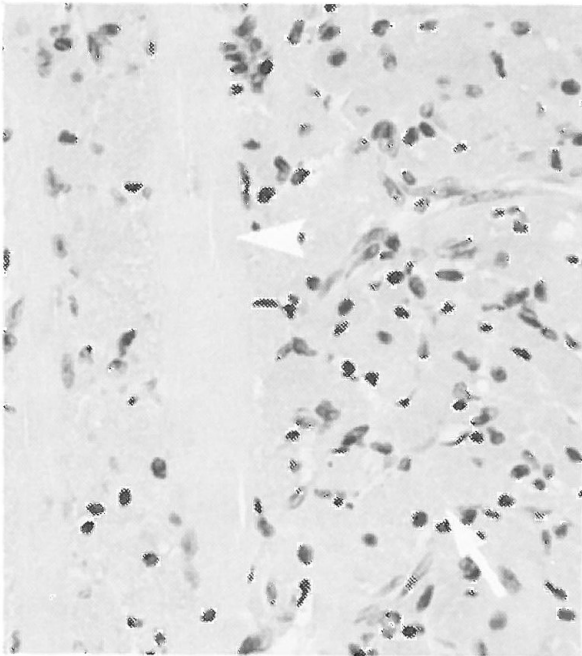


Figure 1. Case 1. Granular cell tumour in the muscle showing polygonal cells with abundant granular cytoplasm (arrow). Isolated muscle fibers were seen in the tumour mass (arrowhead). HE.

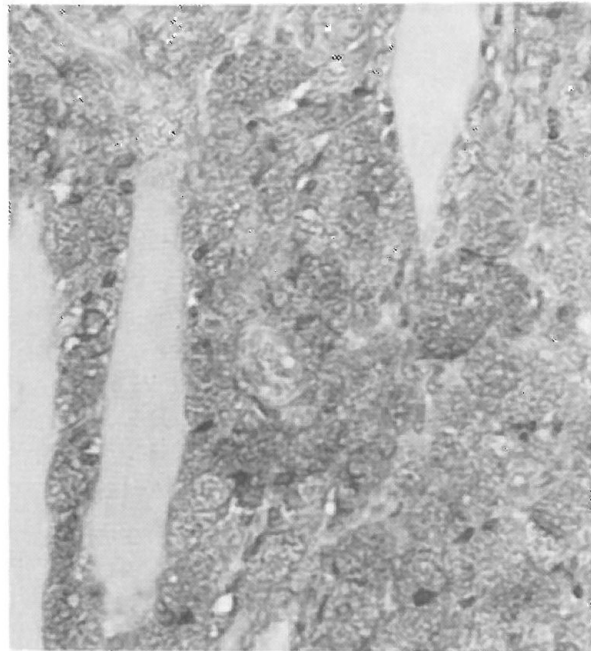


Figure 2. Same tumour as fig. 1 showing large quantities of PAS-positive granules. PAS.

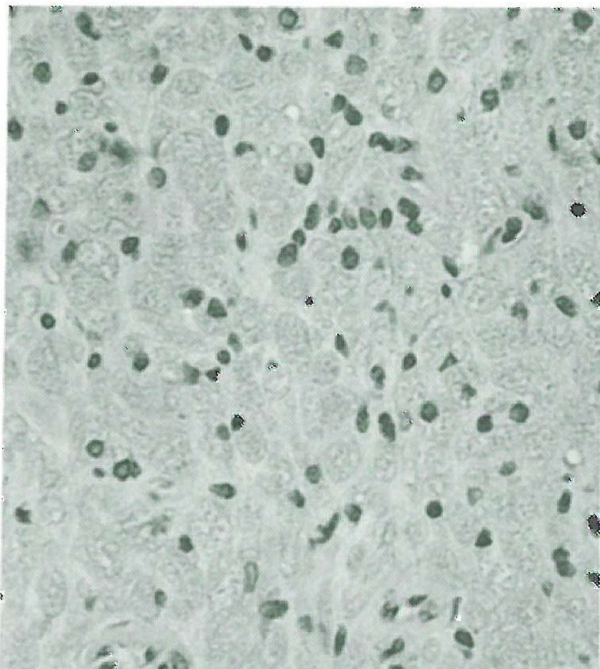


Figure 3. Case 2. Granular cell tumour in the axilla. HE.

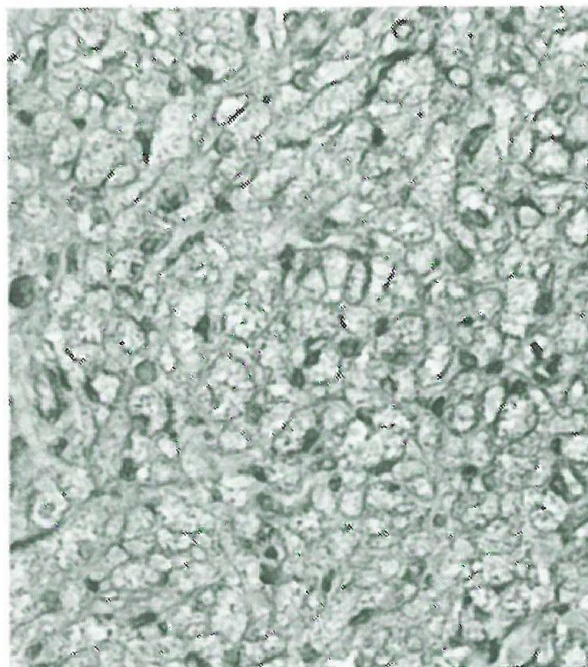


Figure 4. Same tumour as fig. 3 showing moderate amounts of PAS-positive granules.

munohistochemical staining. Based upon the results from the special stains the tumour was classified as a granular cell tumour (Morrison et al. 1987, Sanford et al. 1984, Seiler 1982). Although the tumour invaded the muscular tissue it was judged not to be malignant.

Case 2: A 32-month-old, male Wistar rat. The tumour was found incidentally in the right axillary region at the routine histological examination of the axillary lymph node.

Historically the tumour consisted of large polygonal cells with abundant pink granular and vacuolated (foamy) cytoplasm. The nuclei were round and dark. No mitotic figures were observed. The cells were separated by a scant connective tissue stroma. The tumour was surrounded by a thin layer of connective tissue.

The staining properties of the tumour cells were similar to that of case 1, however the cytoplasm contained lesser amounts of PAS positive, diastase resistant granules. The tumour was classified as a benign granular cell tumour.

Sammendrag

Spontant opståede granular cell tumorer hos rotte ses oftest i hjerne og hjernebinder. I denne artikel beskrives 2 tilfælde af atypisk placering af granular cell tumor, henholdsvis i lårmuskel og axilregion. Begge lokalisationer er derimod beskrevet hos mennesker med denne tumortype. Klassificering af tumorerne er baseret på specialfarvninger (PAS, PAS-diastrase, PTAH og S-100).

Yhteenveto

Jyvössolukasvaimen epätavallinen esiintymispaikka Wistarrotassa.

Spontaanit jyvössolutuumorit esiintyvät rotassa useimmiten aivoissa ja aivokalvoissa. Niitä on raportoitu vain muutaman kerran muualta: vatsaontelon takaosasta, aivolisäkkeestä ja kolmoishermosta. Nyt nämä kasvaimet löytyivät lihaskudoksesta, kainalosta ja reidestä, joka siis poikkeaa tavanomaisesta havainnosta. Toisaalta molemmat tuumorit löytyivät paikasta joka on ihmiseltä raportoitu. Molemmat kasvainlöydöt tehtiin elinikäisen karsinogeenisuustutkimuksen yhteydessä.

References

1. *Maekawa, A., H. Onodera, H. Tanigawa, K. Furuta, M. Takahashi, Y. Kurokawa, T. Kokubo, T. Ogiu, O. Uchida, K. Kobayashi & Y. Hayashi:* Spontaneous tumors of the nervous system and associated organs and/or tissues in rats. *Gann* 1984, 75, 784-791.
2. *Mitsumori K., R. R. Maronpot & G. A. Boormann:* Spontaneous tumors of the meninges in rats. *Vet. Pathol.* 1987, 24, 50-58.
3. *Morrison J. G., G. F. Gray, A. H. Dao & R. B. Adkins:* Granular cell tumors. *Am. Surg.* 1987, 53, 156-160.
4. *Robbins S. L.:* Pathology 1967, vol. II, p. 1320, 3th ed. W. B. Saunders Compagny, Philadelphia.
5. *Sanford S. E., D. M. Hoover & R. B. Miller:* Primary cardiac granular cell tumor in a dog. *Vet. Pathol.* 1984, 21, 489-494.
6. *Seiler R. J.:* Granular basal cell tumors in the skin of three dogs: A distinct histopathologic entity. *Vet. Pathol.* 1982, 19, 23-29.

Referat af Kaninsymposium i Detmold

af Axel Kornerup Hansen, Møllegaards Breeding Center

Den 25.-26. februar havde Altromin Tier-Labor service i samarbejde med Akademie für Tierärztliche Fortbildung arrangeret symposium i Detmold under titlen »Das Kaninchen Zucht, Haltung und Ernährung, sowie das Tier als Modell in Biomedizinischen Versuch«.

Konferencesproget var bortset fra et enkelt indlæg tysk og de 88 deltagere kom derfor fortrinsvis fra tysktalende lande. Herudover var der nogle få deltagere fra Danmark, Sverige, Finland og Holland. Deltagerne var fortrinsvis folk, der selv udførte forsøg med kaniner.

Symposiet blev afholdt i et velegnet auditorium på et kartoffelforskningsinstitut. Symposiets emner spændte bredt fra meget praktisk belærende indlæg som W. Kusch's om avl og opdræt til B. Jilges mere teoretiske om kaniners circadianrytme. Jann Hau gav i sit indlæg nogle gode praktiske retningslinier for brugen af kaniner til antistofproduktion, et område, hvor kaniner vel nærmere tjener som produktionsapparat end som egentligt forsøgsdyr. I flere indlæg, bl.a. af K. Rapp fra Hannover, omtaltes, at man på trods af tidligere manglende tiltro herpå, er ganske langt fremme med kaniner, der er indavlet eller selekteret m.h.p. bestemte egenskaber, f. eks. har han selv etableret 2 linier med henholdsvis høj og lav frekvens

af atherosclerosis. B. Karbowski fra Münster redegjorde for en metode til at anvende kaninen som operationsobjekt m.h.p. genskabelse af passage efter induktion af en tyndvægget hydrosalpinx lig den der ses hos visse ufrugtbare kvinder. T. Brill fra München gennemgik knæleddet hos kaninen netop for at illustrere, at man skal være varsom med umiddelbare sidestillinger mellem kaninens og menneskets anatomi, i forbindelse med kirurgiske forsøg. De fleste indlæg gav tilsyneladende et godt udbytte for tilhørerne, og der var da også en god debat efter hvert indlæg, flere gange på et højt kvalificeret niveau, andre gange på et lidt lavere, f. eks. synes fordele og ulemper ved forskellige metoder til blodtapning hos kaniner efterhånden at måtte være uddebateret.

Den første aften var Altromin vært ved en middag på landsdelsmuseet i Detmold, et arrangement, der gav et godt indtryk af flere sider af den tyske kultur. Inden hjemrejsen blev vi vist rundt hos Altromin.

Alt i alt var der tale om et godt symposium, der gav god lejlighed til at møde andre i samme felt. Man må dog sige, at emnerne SPF-kvalitet, moderne avlssystemer og kaninens rolle i den nyere bioteknologi også godt kunne have været berørt.