

## Fluorochrome Bone Labeling in Sheep

by Horst Balling<sup>1</sup>, Carolin Schuhmacher<sup>2</sup>, Arnulf Weckbach<sup>1</sup> & Thomas R. Blattert<sup>1</sup>.

<sup>1</sup>Trauma & Reconstructive Surgery, Wuerzburg University Hospital, Josef-Schneider-Str. 2, D-97080 Wuerzburg, Germany, <sup>2</sup>Pharmacy, Wuerzburg University Hospital, Josef-Schneider-Str. 2, D-97080 Wuerzburg, Germany. Correspondence: Thomas R. Blattert, M.D. Trauma & Reconstructive Surgery, Wuerzburg University Hospital, Josef-Schneider-Str. 2, D-97080 Wuerzburg, Germany, Phone & Fax: +49 931 / 201 – 31253, E-Mail: blattert@chirurgie.uni-wuerzburg.de

### Summary

As an efficacy model, thirty-four female Merino sheep underwent transpedicular lumbar interbody fusion with three different materials for augmentation of the spine. Fluorochrome analysis was used to evaluate differences in bone deposition and fusion processes between the three study groups. During the post-operative follow-up period of eight weeks, the fluorescent dyes xylenol orange, calcein green, and doxycycline yellow were given at two, four, and six weeks, respectively. All dyes were administered intravenously after sedation with xylazine.

The objective of this paper is to provide a methodical description of preparation, quality control, administration, efficacy, and observed adverse events from the use of these bone labels in sheep.

Both xylenol orange and calcein green dyes provided satisfying results, but doxycycline yellow led to only weak fluorescence in the first ten animals. Consequently, higher dosing was introduced to obtain bright bands in the histological sections. Also, during administration of doxycycline yellow, mild to severe adverse events occasionally occurred: Eight of the first ten sheep suffered from respiratory distress, and in severe cases several stopped breathing, thus requiring immediate intervention. Minimizing the sedative dose and elongating the sedation/doxycycline administration interval were effective changes to the original procedure. We conclude that these adverse events may have been

caused by too high a dose of sedative, as well as a drug interaction between xylazine and doxycycline yellow.

### Introduction

By use of a sheep model, the authors are currently evaluating a new method for transpedicular lumbar interbody fusion (TLIF) of the spine (Blattert, Dellling, Dalal *et al.*, 2002). As an ancillary to this work, documentation of bone deposition over time and fusion process was considered an important endpoint to investigate the success or failure of the TLIF procedure. The investigators decided that fluorochrome labeling would provide a way to assess time to spinal fusion and to estimate new bone formation in this spine fusion model.

The intravenous administration of bone labels ultimately alters the inherent fluorescent ability of the newly formed bone at the TLIF defect site. Bone labels bind to inorganic components, e.g. calcium ( $Ca^{2+}$ ), of mineralized bone (Milch *et al.*, 1958; Rahn & Perren, 1975). The utility of this is that the investigator can mark bone formation at a specific time post-operatively. A bone label will increase the energy level of electrons after excitation with energetic radiation, e.g. ultraviolet light, and these then emit electromagnetic radiation upon returning to their equilibrium energy state as fluorescence visible to the microscopist and of a color dependent on the dye. Sequential use of multiple bone labels, preferably with different fluorescent properties, will allow the

investigator to mark multiple time-points and qualitatively as well as quantitatively measure bone formation over time (Rahn *et al.*, 1980). The investigator can then estimate bone formation at different stages of growth by using different light filters that allow only distinct frequency bands to be seen. The current literature does not provide in-depth data for bone labeling in sheep. Distinct procedures for preparation, quality control, administration, and possible adverse events of fluorochrome dyes are essential for future orthopaedic models in sheep. The objective of this paper is to describe the technique utilized and to provide important guidelines for safe and efficient application.

#### **Materials and Methods**

The experimental protocol was approved by the Institutional Animal Care and Use Committee of the Regional Government Authority of Subfrancia, Germany. All procedures have been performed in accordance with national legislation and The Council Directive of the European Communities on the Protection of Animals Used for Experimental and Other Scientific Purposes (L358/1, November 24, 1986).

The animals used for this study were adult female Merino sheep (n = 34) with a mean age of 13 ± 4 months (range 8 to 28) and mean body weight of 55 ± 5 kg (range 41.9 to 65.0). All animals underwent the TLIF procedure using an internal fixator (USS, Synthes, Umkirch, Germany) for posterior instrumentation and three different treatments for augmentation of the anterior column. Each sheep had posterior instrumentation placement and removal of the L4/L5 intervertebral disc via the transpedicular pathway under endoscopic control (Blattert, Delling & Weckbach, 2002). Augmentation of the anterior column was provided with one of three treatments: The autograft group (n = 10, sheep nos. 1-10) were augmented by transpedicular impaction of autologous bone harvested from the iliac crest, the hydroxyapatite cement group (n = 12, sheep nos. 11-22) were given a bone graft substitute consisting of hydroxyapatite (BoneSource™, Stryker Howmedica-Osteonics, Mahwah, New Jersey), and the OP-1 enhanced cement group (n =

12, sheep nos. 23-34) were given a composite of hydroxyapatite and recombinant human osteogenic protein-1 (rhOP-1 or rhBMP-7).

Postoperatively, the animals were held in separate pens for two days for monitoring and recovery. Pain control was performed with anticipatory i.m. analgesic-injection. The animals were then transferred into another pen where they stayed until day 14 when the stitches were removed. From then, the animals were kept in an open air enclosure for the remainder of the study.

The fluorochrome labels xylenol orange and calcein green were prepared as described in Table 1. Sterilization of the dye solutions by autoclaving (2 bar for 20 min at 121 °C) was tested but failed (Tables 2a and 2b). Xylenol orange developed foam during water dilution post-sterilization and calcein green lost the property of showing fluorescence in daylight. Both dyes showed an increase in pH. Therefore, the preparations were formulated and sterile-filtered under aseptic conditions using a laminar air flow hood (Table 1). All dyes were stored in the dark and refrigerated at +5°C.

Quality control measurements were performed to ensure consistent dye formulations for the duration of the study. Physicochemical stability of xylenol orange and calcein green preparations was assessed on post-production days 0, 1, 4, 12, 14, 28, and 36 for quality control. UV-photometry of the sterile-filtered xylenol orange was performed on day 14. Long-term stability tests (pH, osmolality, microbiological testing) were done more than one year after production, and showed some deterioration. Hence, none of the dyes were stored for more than four weeks, but were manufactured and provided a few at a time when required. The doxycycline yellow was premanufactured as a readily available injectable antibiotic requiring minimal dilution with sterile 0.9 % NaCl solution. Therefore, no quality control assessment of this dye was provided in this laboratory. However, the manufacturers were obliged to indicate expiry dates for every lot.

The three fluorochrome labels were administered in the following dose concentrations (Tables 1, 3 and 4):

- (1) Xylenol Orange (Sigma-Aldrich,

**Table I**

**Specifications on xylenol orange and calcein green**

<u>Type of dye</u> CAS-no.	<u>Xylenol orange 90 mg/ml</u> 63721-83-5	<u>Calcein green 30 mg/ml</u> 1461150
<u>Composition (100 ml)</u>	Xylenol orange (Sigma-Aldrich, Taufkirchen, Germany, article-no. X-0127) 9,0 g + water for injection ad 103.72 g	Calcein green (Synopharm, Barsbüttel, Germany, article-no. 700335) 3,0 g + water for injection ad 101.28 g
<u>Production (100 ml)</u>	The dye is dissolved in approximately 80 g water for injection using a magnetic stirrer. pH-value of 7.20 – 7.40 (xylenol orange) or 7.20 – 7.80 (calcein green), respectively. is adjusted by using 1 N NaOH or 1 N HCl. Water for injection is added to reach total weight.	
<u>In-process-control</u>	pH: 7.20 – 7.40	
<u>Filtration (aseptic conditions: laminar air flow, cleanroom class 100)</u>	The solution is sterile-filtered in a two step procedure using a folded filter paper and a 0.2 µm filter (Minisat RC).	
<u>Assembling (aseptic conditions: laminar air flow, cleanroom class 100)</u>	The preparation is filled in vials (made of glass tubing with the hydrolytic resistance class I, clear), sealed with injection stopper (chloro-butyl; type 1771/4104/40/grey/Proved clean packaged à 200 pieces) and aluminum cap.	
<u>Final control</u>	pH: 7.20 – 7.40 Osmolality: 440 – 485 mosm/kg	pH: 7.20 – 7.40 Osmolality: 115 – 135 mosm/kg
<u>Physicochemical stability</u>	4 weeks	
<u>Storage</u>	+ 3 to + 7 °C	

Table 2a

Physicochemical properties of xylenol orange 90 mg/ml (Lot-no. S00-116) before and after sterilization (2 bar, 20 min, 121 °C)

Xylenol orange 90 mg/ml	before sterilization	after sterilization
pH-value	7.23	8.46
Fluorescent property in daylight	-	-
Foaming in water	-	+

Table 2b

Physicochemical properties of calcein green 30 mg/ml (Lot-no. S00-117) before and after sterilization (2 bar, 20 min, 121 °C)

Calcein green 30 mg/ml	before sterilization	after sterilization
pH-value	7.30	8.45
Fluorescent property in daylight	+	-
Foaming in water	-	-

Table 3

Dyes and their dosages

Dye	Dosage
Xylenol orange 90 mg/ml	1.00 ml/kg bodyweight
Calcein green 30 mg/ml	0.33 ml/kg bodyweight
Doxycycline yellow 20 mg/ml	1.00 ml/kg bodyweight (sheep 1-10) 2.0 g/animal* (sheep 11-34)

\* recommended dosage

Taufkirchen, Germany): The intended dose was 1 ml dye solution/kg body weight. The dose concentration was 90 mg dye/ml dose solution. The dose volume was 100 ml with additional volume made-up with sterile 0.9 % NaCl solution. The route of administration was via i.v. drip at a rate of 42 ml/min. This dye was given on post-TLIF day 14 (Figure 1).

(2) Calcein Green (Synopharm, Barshuettel, Germany): The intended dose was 0.33 ml dye solution/kg body weight. The dose concentration was 30 mg dye/ml dose solution. The dose volume was 100 ml with additional volume made-up with sterile 0.9 % NaCl solution. The route of administration was via i.v. drip at a rate of 42 ml/min. This dye was given on post-TLIF day 28 (Figure 2).

(3) Doxycycline Yellow (Doxyhexal<sup>®</sup> SF: Hexal, Holzkirchen, Germany): The intended dose was 1.0 ml dye solution/kg body weight. The dose concentration was 20 mg dye/ml dose solution. The dose volume was 500 ml with additional volume made-up with sterile 0.9 % NaCl solution in autograft group (sheep nos. 1 - 10). Hydroxyapatite alone and hydroxyapatite with rhOP-1 groups (sheep nos. 11 - 34) received 2 x 50 ml of Doxyhexal<sup>®</sup> SF regardless of body weight that corresponded to a total of 2.0 g of doxycycline, completed to 2 x 250 ml with 2 x 200 ml of sterile 0.9 % NaCl solution, given at an interval of four to eight hours between the two applications. The route of administration was via i.v. drip at a rate of 42 ml/min. This dye was given on post-TLIF day 42 (Figure 3).



Table 4  
Xylazine (Rompun<sup>®</sup> 2%) and dye doses applied to each sheep

Sheep no	Bodyweight [kg]	Xylazine [ml]	Xylcnol orange [ml]	Xylazine [ml]	Calcein green [ml]	Xylazine [ml]	Doxycycline yellow [g]
1	61.5	1.3	61.5	1.5	20.5	1.5	1.54
2	62.0	1.5	62.0	1.5	20.7	1.5	1.55
3	57.1	1.5	57.0	1.5	19.0	1.5	1.425
4	60.0	1.5	60.0	1.5	20.0	1.5	1.50
5	53.5	1.3	53.5	1.3	17.8	1.3	1.34
6	60.0	1.5	60.0	1.5	20.0	1.5	1.50
7	57.2	1.4	57.2	1.5	19.0	1.5	1.43
8	56.5	1.5	56.5	1.5	18.8	1.0	1.43
9	55.0	1.3	55.0	1.2	18.0	0.8	1.38
10	52.4	1.3	52.4	1.3	17.5	0.8	1.31
11	51.0	1.3	51.0	1.2	17.0	1.0+0.5	1.00+1.00
12	58.0	1.0	58.0	1.0	19.0	1.0+0.8	1.00+1.00
13	55.5	1.1	55.5	1.0	18.5	0.9+0.0	1.00+1.00
14	56.0	1.1	56.0	0.9	19.0	0.9+0.0	1.00+1.00
15	55.0	1.1	55.0	1.0	18.5	0.5+0.0	1.00+1.00
16	57.3	1.2	57.3	1.0	19.0	0.5+0.0	1.00+1.00
17	57.0	1.3	57.0	1.4	19.0	0.8+0.0	1.00+1.00
18	65.0	1.3	65.0	1.4	22.0	0.8+0.0	1.00+1.00
19	61.3	1.3	61.0	1.0	20.5	0.8+0.0	1.00+1.00
20	55.6	1.0	55.6	1.0	18.8	0.8+0.0	1.00+1.00
21	55.1	1.0	59.0	0.5	20.0	0.4+0.0	1.00+1.00
22	56.4	1.0	60.0	1.0	20.0	0.8+0.0	1.00+1.00
23	63.0	0.8	63.0	0.8	21.0	1.0-0.0	1.00+1.00
24	59.0	1.0	59.0	1.3	20.0	0.5+0.0	1.00-1.00
25	63.0	0.8	63.0	0.8	21.0	0.5+0.0	1.00+1.00
26	52.0	0.8	52.0	0.8	18.0	0.5+0.0	1.00+1.00
27	51.0	0.8	51.0	0.8	17.0	0.5+0.0	1.00+1.00
28	50.0	0.8	50.0	0.8	17.0	0.5+0.0	1.00+1.00
29	48.5	0.8	48.5	0.8	17.0	0.8+0.0	1.00+1.00
30	50.0	1.0	50.0	0.8	17.0	0.5+0.0	1.00+1.00
31	46.4	0.9	47.0	0.8	16.0	0.5+0.0	1.00+1.00
32	45.7	0.9	46.0	0.8	15.5	0.5+0.0	1.00+1.00
33	41.9	0.8	42.0	0.8	14.0	0.5+0.0	1.00+1.00
34	43.3	0.8	44.0	0.8	15.0	0.5+0.0	1.00+1.00

Dose administration of each dye was via i.v. catheter. We used 22 gauge catheters placed in an auricular vein after intramuscular xylazine sedation (Rompun<sup>®</sup> 2%: 0.4 to 1.5 ml, Table 4). The animals were sacrificed eight weeks post-operatively with a single dose of 1.5 or 2.0 ml xylazine i.m., followed by 100 to 500 mg ketamine (Ketanest<sup>®</sup>, Ketavet<sup>®</sup>) i.m. for anesthesia. At time of sacrifice (eight weeks post-TLIF), each sheep was given an intravenous lethal dose of 5 to 15 ml T61<sup>®</sup> (combination of embutramid narcotic,

mbezonium-iodide depolarisant, and tetracaine local anesthetic). The lumbar spine segment L3 to L6 was harvested and processed for undecalcified histology. Bone labels will fade with decalcification because the labels bind to Ca<sup>2+</sup> in the newly formed bone. Coronal sections (15µm) were examined with a special microscope for fluorescence analysis using a UV-light microscope. Microphotography was digitalized for documentation and for the qualitative evaluation of bone formation.

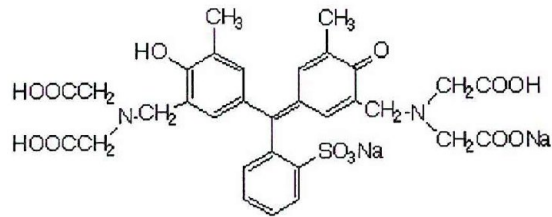


Fig. 1: Structural formula of xlenol orange

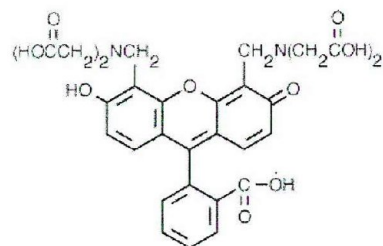


Fig. 2: Structural formula of calcein green

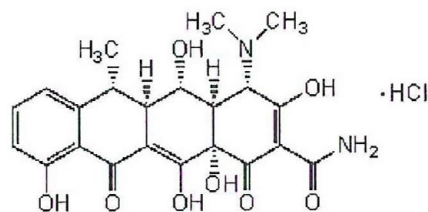


Fig. 3: Structural formula of doxycycline yellow (=α-6-Deoxy-5-hydroxytetracycline)

### Results

OP-1 enhanced cement yielded an interbody fusion rate of 10/12 after eight weeks. In contrast, solid fusion was observed in only 1/10 cases in the autograft group, and in 2/12 cases in the hydroxyapatite group only (Table 5) (Blatter, Delling, Dalal et al., 2002). Fluorochrome labeling was a useful tool in the observation of these clinically important findings, since it enabled assessment of the time of bony on-growth, osseous remodeling, and spinal fusion. The xlenol orange label showed that within two weeks post-TLIF no

significant intervertebral bone formation process had occurred, because there was no xlenol orange label in the sections. New bone formation was evident at four and six weeks with the observation of calcein green and doxycycline yellow labels (Figures 4a and 4b).

The results of the quality control assessment are listed in Tables 6, 7, and 8. Measurements of pH and osmolality were consistent throughout the study (Tables 6 and 7). Assessment of bacterial growth turned out to be negative, sterility was maintained (Tables 8a and 8b). UV-spectroscopy

Table 5  
Results of the overall study

Treatment-group	n	Fusion incidence	Hyperventilation incidence
<u>Autograft</u>	<u>10</u>	<u>1</u>	<u>8</u>
<u>Hydroxyapatite</u>	<u>12</u>	<u>2</u>	<u>2</u>
<u>rhOP-I enhanced hydroxyapatite</u>	<u>12</u>	<u>10</u>	<u>0</u>

of a xylanol orange sample performed on day 14 post-production showed equal absorption ( $A_1 = 0.611$ ) compared to a fresh sample of the same dye ( $A_2 = 0.612$ ) ensuring physicochemical stability (Figure 5). However, comparing the dyes' osmolality on the day of production and more than one year later, the samples' alterations are too serious (osmolality-increase of xylanol orange: ca. 5.5 % of calcein green: ca. 9 %) (Tables 8a and 8b), although the long-term value still fits the production's final-control criteria for acceptable dyes (Table 1). Therefore, it seems that destructive processes may have taken place; this is especially true for calcein green. Note that doxycycline yellow preparations were not assessed for quality control since they were produced by the supplier.

All animals showed specific reactions to the application of xylanol orange and calcein green. Discoloration of skin and mucous membranes were evident only a few seconds after initiation of i.v. dosing. This discoloration was manifested as a distinct violet stain. Urine was stained purple as well. The visible effect of calcein green was weak. A change in urine color was not detected and only well-vascularized tissues were stained yellow. No animal experienced severe ventilation distress or presented signs of discomfort as the xylanol orange and calcein green dyes were applied. Moreover, we did not notice severe dyspnea or muscular hypertonus after increasing infusion rates. The animals regained their normal color of skin, mucous membranes, and urine in a few hours post-administration.

Doxycycline yellow infusion was more problem-prone than the other bone labels. A need for a higher infusion volume due to the weak fluorescence of tetracycline derivatives (Sun *et al.*, 1992) demanded a longer application time. This extended infusion led to adverse events in the animals. Eight of ten autograft animals showed

signs of respiratory distress within the first fifteen seconds of administration. Apnea occurred in five of the eight for more than a ten second duration, but no animal died from this complication. The dose administration regimen required changes to alleviate respiratory complications. A preliminary solution was to alter the infusion rate. The rate was reduced for a short period of time until the animals recovered to normal breathing depth and frequency. In severe cases of apnea, the infusion was stopped and animals re-positioned supine. Ventilation was applied by manual thoracic compression. Another change was made to the infusion regime by cutting the single 500 ml administration to 2 x 250 ml administrations. This change provided a break period between the two administrations of four to six hours for recovery. Unfortunately, the following two animals dosed experienced similar respiratory complications as before. Additional changes included: (1) keeping the infusion catheter in the auricular vein so the sheep did not need a second xylazine sedation for another i.v.-catheterization, (2) reduction of the xylazine dose to a level of approximately 0.01 ml/kg body weight which still was high enough to guarantee proper sedation, and (3) further delay in the time periods between sedation/first dye administration (15 to 20 minutes) and first dye/second dye administration (8 hours). The final change was successful in the remainder of the sheep. No dyspnea complications were noted (Table 5).

#### Discussion

This paper is the first to describe in detail the methodology and feasibility of the multiple bone label use in sheep. The topics of interest were dye preparation, quality control, administration, and adverse effects from the use of xylanol orange, calcein green, and doxycycline yellow bone labels.

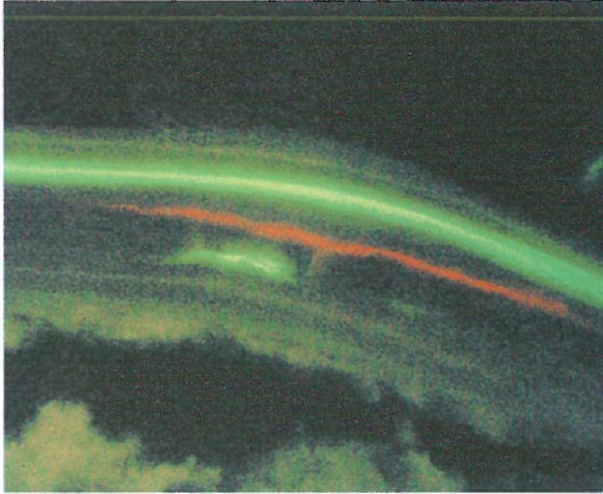


Fig 4a

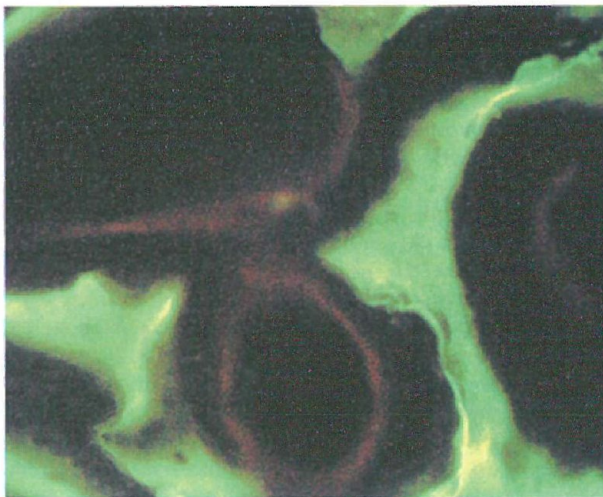


Fig 4b

Figs. 4a, b: Photomicrographs from unstained, undecalcified sections (thickness 15  $\mu\text{m}$ ) made in ultraviolet light (sheep-no. 3): parallel fluorochrome bands with distinct xylene orange mark (2 weeks after surgery) in the intravertebral area of L4 (Fig. 4a); no xylene orange marks in the intervertebral space L4/5 where osseous fusion occurred; in this area only calcein green (4 weeks after surgery) and doxycycline yellow bands (6 weeks after surgery) visible (Fig. 4b); note the faint intensity of the doxycycline band during the primary staining regimen for sheep-nos. 1-10.



Table 6:

pH-value and osmolality of administered xylenol and calcein dyes on day 0 (= day of production)

Xylenol orange 90 mg/ml			Calcein green 30 mg/ml		
Lot-no.	pH	Osmolality [mosm/kg]	Lot-no.	pH	Osmolality [mosm/kg]
<u>S00-116</u>	<u>7.23</u>	<u>482</u>	<u>S00-117</u>	<u>7.30</u>	<u>130</u>
<u>S00-137</u>	<u>7.27</u>	<u>480</u>	<u>S00-138</u>	<u>7.23</u>	<u>130</u>
<u>S00-167</u>	<u>7.25</u>	<u>448</u>	<u>S00-168</u>	<u>7.32</u>	<u>120</u>
<u>S00-183</u>	<u>7.23</u>	<u>440</u>	<u>S00-184</u>	<u>7.40</u>	<u>123</u>
<u>S00-208</u>	<u>7.24</u>	<u>442</u>	<u>S00-222</u>	<u>7.36</u>	<u>157*</u>
<u>S00-232</u>	<u>7.25</u>	<u>461</u>	<u>S00-246</u>	<u>7.27</u>	<u>132</u>
<u>S00-247</u>	<u>7.21</u>	<u>452</u>	<u>S01-61</u>	<u>7.27</u>	<u>155*</u>
<u>S01-46</u>	<u>7.20</u>	<u>458</u>	<u>S01-74</u>	<u>7.35</u>	<u>122</u>
<u>S01-60</u>	<u>7.23</u>	<u>466</u>			
<u>S01-73</u>	<u>7.22</u>	<u>442</u>			

\* Higher osmolality due to use of hydrochloric acid for pH-regulation

Table 7a:

Physicochemical parameters of xylenol orange 90 mg/ml (Lot-no. S00-116) on days 0, 4, 12, 14, 28, and 36 after production

Xylenol orange 90 mg/ml	pH	Osmolality [mosm/kg]
day 0	7.23	482
day 4	7.29	*
day 12	7.32	*
day 14	*	481
day 28	*	480
day 36	*	472

\* parameter not measured

Table 7b:

Physicochemical parameters of calcein green 30 mg/ml (Lot-no. S00-117) on days 0, 4, 12, 14, 28 and 36 after production

Calcein green 30 mg/ml	pH	Osmolality [mosm/kg]
day 0	7.30	130
day 4	7.50	127
day 12	7.40	115
day 14	*	130
day 28	*	129
day 36	*	126

\* parameter not measured

Table 8a:

Long-term stability of physicochemical and microbiological parameters of xylene orange 90 mg/ml (Lot-no. S00-183) on day 405

Xylene orange 90 mg/ml Lot-no. S00-183	pH	Osmolality [mosm/kg]	Result of microbiological testing
day 0	7.23	440	*
day 405	7.27	464	negative

\* parameter not measured

Table 8b

Long-term stability of physicochemical and microbiological parameters of calcein green 30 mg/ml (Lot-no. S00-184) on day 405

Calcein green 30 mg/ml Lot-no. S00-184	pH	Osmolality [mosm/kg]	Result of microbiological testing
day 0	7.40	123	*
day 405	7.42	134	negative

\* parameter not measured

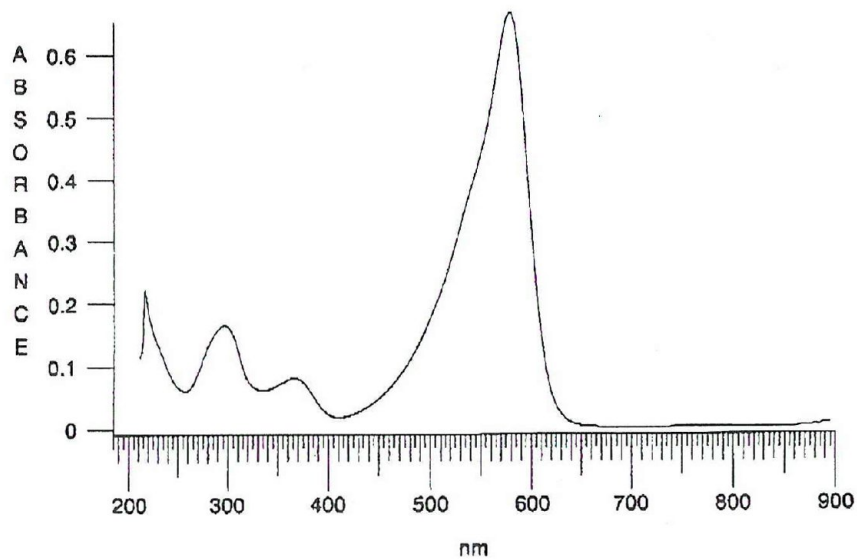


Fig. 5: UV-spectroscopy of xylene orange in 0.1 N sodium hydroxide ( $\lambda_{max} = 580 \text{ nm}$ )

The advantage of these labels was that they allow one to assess the quality of fusion in this clinically-applicable model.

Long-term testing (> 1 year) of physicochemical stability for xylenol orange and calcein green solutions showed however an osmolality increase that exceeded the tolerance measurement range. Therefore, the authors recommend using these within four weeks after production.

Rahn and Perren (1971) administered xylenol orange using the same dosage as described here. They reported no complications such as dyspnea. Neither did we notice complications in cases of xylenol orange or calcein green labeling. Adverse events, such as breathing distress, apnea and nausea, were only seen in the doxycycline yellow application. For this observation, different reasons are possible: The xylazine dose may have been too high as this is an  $\alpha_2$ -adrenergic agonist and has cardiorespiratory effects in ruminants. Additionally, sheep might present severe reactions especially on repetitive application of xylazine. A drug interaction between doxycycline and xylazine may also exist, since reduction of the sedative agent and delayed dye application apparently helped to eliminate respiratory distress. Further research has to be performed to definitely solve this problem.

Weak fluorescence signal coupled with possible adverse effects from doxycycline administration forced several changes to the original infusion procedure. Animals were experiencing respiratory distress with apnea in severe cases. Procedural changes consisted of dividing the increased total dose of dye to allow animal recovery during dye administration, reducing sedation dose and number of dosings, and increasing the period of time between sedation and dye administration. All of these changes resulted in minimal complications with satisfactory histological results.

Our observations of adverse events associated with all three dye administrations can be summarized with the following recommendations:

1) The required amount of doxycycline yellow (2.0 g / animal) should be given as two well-separated doses in order to avoid hazardous volume overload caused by the dissolution agent.

2) Minimal xylazine sedation dosing reduces adverse events that occur in combination with doxycycline yellow administration.

3) An interval of 15 to 20 minutes between sedation and doxycycline yellow application minimizes interaction reactions of the drugs.

4) Keeping the i.v. catheter in the auricular vein obviates a second dose of xylazine sedative for the delayed doxycycline yellow administration. The literature provided information on possible adverse effects for xylazine and doxycycline yellow (Table 9). Xylazine has been shown to have its own effects on animal physiology, e.g. for its potential to induce hypoxemia (Doherty *et al.*, 1986; Papazoglou *et al.*, 1995; Raptopoulos *et al.*, 1995), regurgitation (Hikasa *et al.*, 1992), and decrease in pH and  $P_2O_2$  (Ludders *et al.*, 1989). We did observe changes to respiration in these sheep, but only in conjunction with the administration of doxycycline yellow dye.

In agreement with Stuart and Smith (1992), the dose concentrations of xylenol orange and calcein green led to satisfying results. In contrast, fluorescence of doxycycline yellow produced mediocre results. Original dose concentration of 1.0 ml Doxyhexal<sup>®</sup> SF/kg body weight, administered intravenously, were changed to bodyweight-independent applications of 2.0 g/sheep. This change was successful in increasing the quality of doxycycline yellow fluorescence. The fluorochrome dye alizarin red was never considered as an alternative for doxycycline yellow in this study for two reasons: First, its chromatic characteristics resemble those of xylenol orange (Rahn & Perren, 1975), which may have caused problems in differentiating those two dyes in the histological sections. Second, adverse events are described for the use of alizarin red. The dosage required for bone labeling reaches the LD50 i.v. threshold in mice (Rahn & Perren, 1975) and sheep (Magin & Delling 2001).

#### Acknowledgements

The authors wish to thank the following individuals for their technical support:

Wuerzburg University: M. Anetseder, R. Endl, W. Geise, S. Pantzner, A. Reichert, A. Thiede, K. Ulrichs. Hamburg University: G. Delling, Stryker

Table 9:

Pharmacological side effects of xylazine and doxycycline

Xylazine	Doxycycline
o Hypoxia	o Hypersensitivity reaction of the skin
o Respiratory distress	o Phototoxic reactions of the skin
o Apnea	o Delayed progression of bone growth (reversible)
o Increase of salivation	o Increase of intracranial pressure
o Decrease of gastrointestinal motility	o Myopia (reversible)
o Regurgitation	o Irreversible changing of color of teeth in children aged < 8 years
o Paralysis of the tongue	o Hoarseness, dysphagia
o Uterinal contractions	o Gastrointestinal dysfunction
o Decrease of blood pressure after initial rise of blood pressure	o Thrombophlebitis
o Bradycardia and bradypnoea	o Bronchial spasms
o Heart rhythm alteration	o Blood count alterations
o Failure of temperature regulation	o Superinfection with bacteria or yeastlike fungus
o Paradox excitation	o Liver damage in case of an overdose
o Hyperglycemia and polyuria	o Pancreatitis in case of an overdose
o Reversible local tissue irritation	
o Nausea and vomiting	



Biotech: A. Pierce. K. Reali.

This work is based on a study investigating lumbar interbody fusion techniques in sheep by Wuerzburg University Hospital, Trauma & Reconstructive Surgery, Germany; Hamburg-Eppendorf University Hospital, Department of Bone Pathology, Germany; Stryker Biotech, Hopkinton, Massachusetts, USA. The study was performed at Wuerzburg University Hospital, Trauma & Reconstructive Surgery, Germany. It was funded in part by Synthes, Umkirch, Germany. The biomaterials for this study were provided by Stryker Biotech, Hopkinton, Massachusetts, USA, but no financial support was granted.

### References

- Blattert TR, G Delling, PS Dalal, CA Toth, H Balling & A Weckbach:* Successful transpedicular lumbar interbody fusion by means of a composite of OP-1 (rhBMP-7) and hydroxyapatite carrier. A comparison to autograft and hydroxyapatite in the sheep spine. *Spine* 2002. (In press).
- Blattert TR, G Delling & A Weckbach:* Pedikuloskopisch assistierte transpedikuläre Spongiosaplastik zur interkorporellen Fusion an der lumbalen Wirbelsäule. Eine tierexperimentelle Untersuchung am Schafmodell. *Unfallchirurg* 2002, *105*, 680-687.
- Doherty TJ, PJ Pascoe, WN McDonnell & G Monteith:* Cardiopulmonary effects of xylazine and yohimbine in laterally recumbent sheep. *Can. J. Vet. Res.* 1986, *50*, 517-521.
- Hikasa Y, S Ogasawara & K Takase:* Alpha adrenoreceptor subtypes involved in the emetic action in dogs. *J. Pharmacol. Exp. Ther.* 1992, *261*, 746-754.
- Ludders JW, J Rode, GS Mitchell & EV Nordheim:* Effects of ketamine, xylazine, and a combination of ketamine and xylazine in Pekin Ducks. *Am. J. Vet. Res.* 1989, *50*, 245-249.
- Magin M N, & G Delling:* Improved lumbar vertebral interbody fusion using rhOP-1. A comparison of autogenous bone graft, bovine hydroxylapatite (Bio-Oss), and BMP-7 (rhOP-1) in sheep. *Spine* 2001, *26*, 469-478.
- Milch RA, DP Rall & JE Tobie:* Fluorescence of tetracycline antibiotics in bone. *J. Bone Joint Surg.* 1958, *40*, 897-910.
- Papazoglou L, D Raptopoulos & G Kounenis:* The effect of xylazine on the isolated sheep trachea. *J. Vet. Pharmacol. Ther.* 1995, *18*, 216-219.
- Rahn BA, FC Bacellar, L Trapp & SM Perren:* Methode zur Fluoreszenz-Morphometrie des Knochenanbaus. *Akt. Traumatol.* 1980, *10*, 109-115.
- Rahn BA, & SM Perren:* Xylenol orange, a fluorochrome useful in polychrome sequential labeling of calcifying tissues. *Stain Technology* 1971, *46*, 125-129.
- Rahn BA, & SM Perren:* Die mehrfarbige Fluoreszenzmarkierung des Knochenanbaus. *Chemische Rundschau* 1975, *28*, 12-15.
- Raptopoulos D, BM Weaver, M Papanastassopoulou, GE Staddon & TJ Parkinson:* The effect of xylazine on plasma thromboxane B2 concentration in sheep. *J. Vet. Pharmacol. Ther.* 1995, *18*, 438-441.
- Stuart AJ & DA Smith:* Use of the fluorochromes xylenol orange, calcein green, and tetracycline to document bone deposition and remodeling in healing fractures in chickens. *Avian diseases*, 1992, *36*, 447-449.
- Sun TC, S Mori, J Roper, C Brown, T Hooser & DB Burr:* Do different fluorochrome labels give equivalent histomorphometric information? *Bone* 1992, *13*, 443-446.