



## Development of concurrent infection of notoedric mange in rabbits infected with *Trypanosoma evansi*

by L. D. Singla<sup>1\*</sup>, Neena Singla<sup>2</sup> & V. R. Parshad<sup>2</sup>

<sup>1</sup>Department of Veterinary Parasitology, Guru Angad Dev Veterinary and Animal Sciences University, Ludhiana-141004, India, <sup>2</sup>Department of Zoology, Punjab Agricultural University, Ludhiana-141004, India.

\*Correspondence: Dr. Lachhman Das Singla, Professor -cum-Head, Department of Veterinary Parasitology, College of Veterinary Science, GADVASDU, Ludhiana-141004, Punjab, India. Phone: +91 161 2414029, Fax: +91 161 2400822, E-mail: ldsingla@gmail.com

### Summary

This report describes observations on the development of cutaneous lesions in rabbits experimentally infected with *Trypanosoma evansi*. Skin scrapings revealed the presence of different developmental stages of *Notoedres cati* var. *cuniculi* and the animals were successfully treated by combined anti-*Trypanosoma* (diminazene aceturate @ 3.5 mg.kg<sup>-1</sup>body weight) and acaricid treatments (doramectin @ 400µg.kg<sup>-1</sup>body weight). *T. evansi* infection probably made the rabbits more prone to infection of notoedric mange and doramectin proved to be effective, practical and well tolerated means of treatment.

### Introduction

*Trypanosoma evansi*, a mechanically transmitted blood protozoan parasite causing trypanosomosis ('surra') is one of the major obstacles to livestock production and health (Gill, 1991). Besides causing disease, the trypanosomes are held responsible for producing a state of severe immunosuppression which renders the host more susceptible to secondary infections and poor response to bacterial and viral vaccines (Holmes, 1980). Mange is one of the serious debilitating and common skin disorder reported in rabbits throughout the world (Davies *et al*, 1991). Transmission among animals is by direct contact and humans are infected rarely (Chakrabarti, 1986). Common hosts of notoedric mange include cats, rats, squirrels, rabbits and bats (Mullen & Oconnor, 2002). Several drugs have been tried against notoedric mange in rabbits with varied efficacy (Singla *et al*, 1996; Chhabra *et al*, 1989; Singari *et al*, 2001; Aulakh *et al*, 2003). Doramectin, a long acting endectocide against ectoparasites with a wide spectrum of activity (Logan *et al*, 1996; Jagannath & Yathiraj, 1999), has been successfully used as a single dose treatment against mange mite in sheep (Bates *et*

*al*, 1995), pigs (Arends *et al*, 1999) and camel (Singh *et al*, 2001). During our studies on the potential of *T. evansi* as biocide of rodent pest species viz. *Bandicota bengalensis* and *Rattus rattus*, *T. evansi* strain was maintained in rabbits which acquired notoedric mange. The objective of the present study is to place on record the development of naturally acquired notoedric mange (due to *Notoedres cati* var. *cuniculi*) in rabbits experimentally infected with *T. evansi* along with its successful treatment.

### Materials and Methods

#### Animals

Sexually mature healthy laboratory bred rabbits between 1-2 years of age (n=8) of both sexes (four each), with mean body weight of 2.43 ± 0.18 kg, were kept in single rabbit metallic cages in a well ventilated room for the maintenance a source of *T. evansi*. The floor, walls and ceiling of the room were smooth and free from cracks and crevices. Rabbits were fed with standard animal diet procured from M/s Ashirwad Industries (Chandigarh), India. During



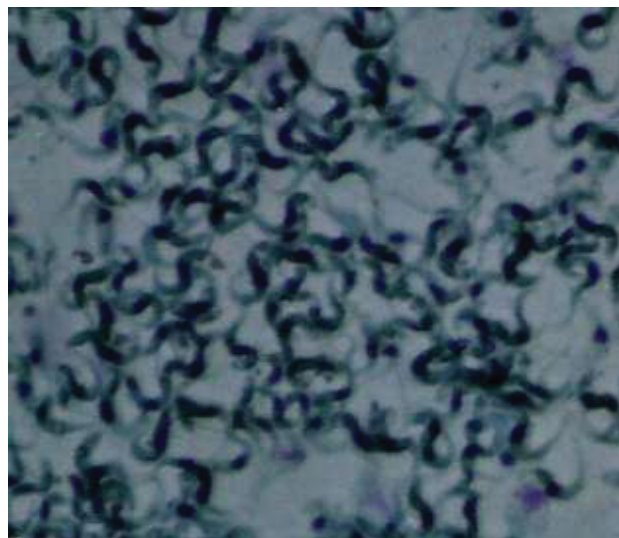
the study period, the temperature and humidity ranged between 22-28°C and 40-60%, respectively. The rabbits had access to natural day light conditions. Animal cages and rooms were cleaned daily. Animals were treated humanely as per the guidelines approved by Institutional Animal Ethics Committee, Punjab Agricultural University (PAU), Ludhiana, India.

### Infection and clinical signs

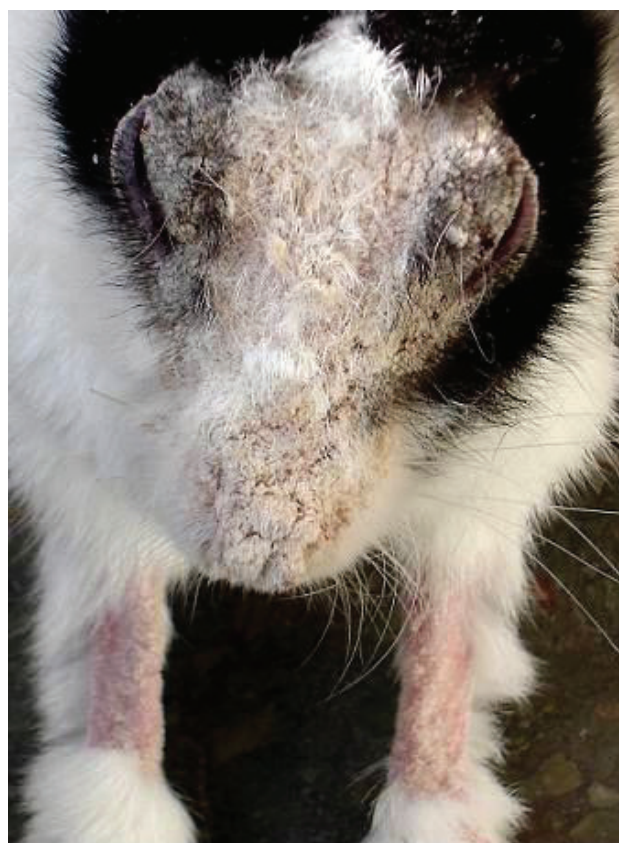
Prior to the use of rabbits for maintenance of *T. evansi*, all the rabbits (both treated and untreated) were checked for the presence of ecto- and endoparasites through blood, fecal and skin scrapings examination. All the rabbits were found negative both for ecto and endoparasites. For maintaining *T. evansi*, five rabbits (two males and three females) with mean body weight of  $2.18 \pm 0.21$  kg were inoculated intraperitoneally with 1 ml of the purified trypanosome (Figure 1) stock containing  $1 \times 10^6$  *T. evansi*. The rabbits developed signs of disease with paroxysms and intermission. The infected rabbits were found to have intense itching, discomfort and loss of fur with patchy exudation from the skin due to dermatitis. This was followed by dry yellowish white crust formation. All the cases presented lesions on the frontal area of head including nose, lips, and eye lids. Three rabbits also showed lesions on pinna and legs (Figure 2). Heavy crust on eyes interfered with vision. The animals were also found depressed and emaciated. These clinical signs and characteristics of lesions were suggestive of mange. Other rabbits (two males and one female with mean body weight of  $2.50 \pm 0.32$  kg) not infected with *T. evansi* remained normal and healthy.

### Diagnosis

Definitive diagnosis was confirmed by microscopic examination of skin scrapings of all the five rabbits. Scrapings of the crusty skin of the affected rabbits were collected, treated with 10% KOH solution and incubated at 37°C for 8 hours followed by centrifugation at 800g for 5 minutes. The supernatant was discarded and the sediment was carefully mixed with saturated glucose solution. Finally, after 10 minutes the upper layer was collected and examined under a stereoscopic microscope to determine the presence of mites. Specific identification of the mites was performed following the description given by Soulsby (1982) and Muller *et al* (1983). Biopsy of skin preserved in 10% neutral buffered formalin was conducted for recording histopathological changes. Skin



**Figure 1.** Giemsa stained smear showing DEAE cellulose purified *Trypanosoma evansi* used for infecting rabbits.



**Figure 2.** Rabbit with lesions of *Notoedres cati* var. *cuniculi* infestation on face, muzzle, eyelids, and limbs. Heavy crust on eyes interfering with vision.

scrapings of healthy, uninfected rabbits were also examined for the presence of mites. These rabbits did not have clinical signs of mange.

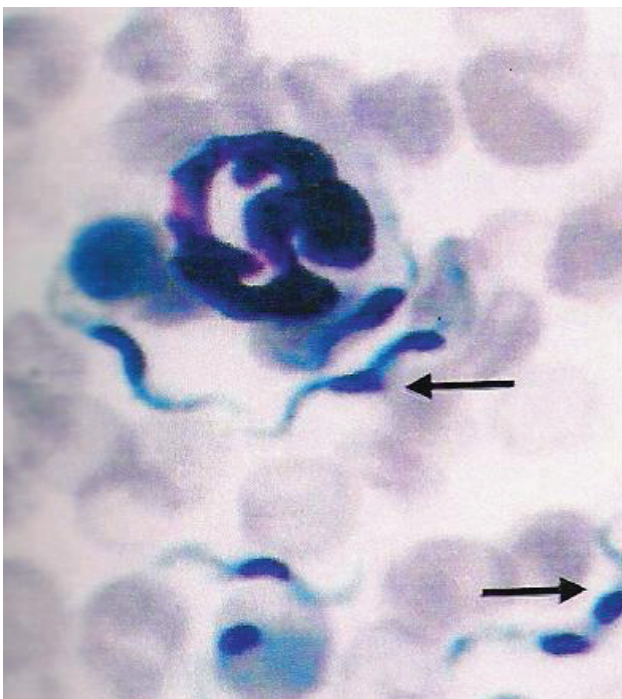
### Treatment

All the infected rabbits were treated with doramectin @ 400 µg.Kg<sup>-1</sup> body weight subcutaneously. The mean



dose of doramectin calculated for 5 infected rabbits was  $872 \pm 83.33\mu\text{g}$  per rabbit with a range of 600 to  $1200\mu\text{g}$  per rabbit. Because of the difficulties associated with topical treatment of rabbits and in administering the small drug volume required i.e. less than  $100\mu\text{l}$  per rabbit, a decision was made to treat all the infected rabbits with a dose of  $0.1\text{ml}$  of  $1\%$  ( $10\text{mg. ml}^{-1}$ ) injectable solution of doramectin (Dectomax, marketed by Pfizer Limited, Pfizer center, Mumbai, India) subcutaneously for notoedric mange. Simultaneously, the uninfected rabbits were also injected with  $0.1\text{ml}$  distilled water subcutaneously. Injection of diminazene aceturate (Berenil, Hoechst India Limited) @  $3.5\text{mg.Kg}^{-1}$  body weight was given along with antihistamine chlorphenamine maleate to treat trypanosomosis.

After the treatment, rabbits were observed daily for general and local adverse reactions, increase or decrease in scratching, restlessness and lesions, reduction in crust, appearance of the hair coat and improvement in general behaviour. Blood smear examination and mouse inoculation tests (Figure 3) were conducted daily for three days and subsequently at fortnightly intervals to diagnose trypanosomosis. Skin scrapings of treated rabbits were obtained after the doramectin treatment on day 3, 7, 10, 15 and then at fortnightly intervals. Follow up evaluations of all the rabbits continued for up to 3 months after doramectin and diminazene aceturate treatment.

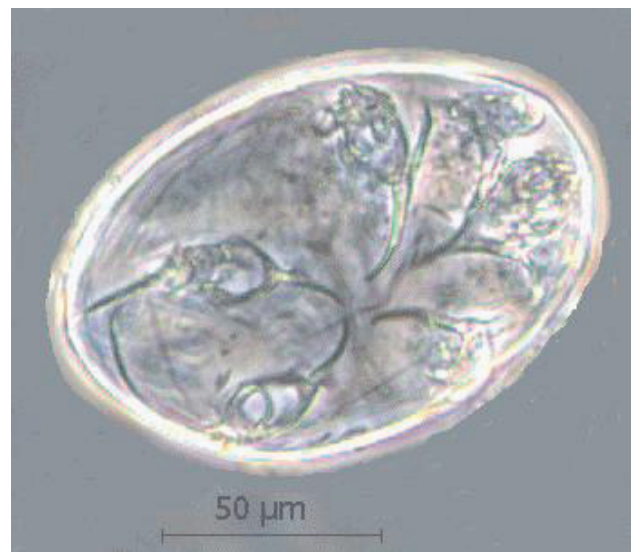

**Figure 3.** Giemsa stained blood smear of mice showing *T. evansi* with longitudinal binary fission. Arrow indicates dividing nucleus.

## Results

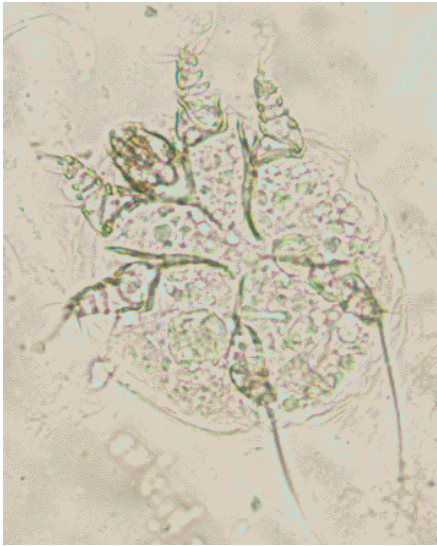### Pre-treatment

Microscopic examination of skin scrapings revealed abundant mites at various developmental stages i.e. egg, egg containing larva, larva, nymph and adult (Figures 4-7) indicating active infection. The number of mites/ $\text{cm}^2$  including all the stages varied from 40 to 120 per skin scraping with a mean of  $78 \pm 13.28$ . The mites were identified as *Notoedres cati* var. *cuniculi* on the basis of long and unjointed pedicels with bell shaped suckers on tarsi (Figures 6-7), location of anus at dorsum (Figure 7) and lacking of dorsal spines which differentiates *Notoedres* spp. from *Sarcoptes* spp. as per the description given in Muller *et al* (1983). Skin biopsy revealed changes in the epidermis varying from inflammation (with infiltration of eosinophils, lymphocytes, fibroblasts and neutrophils), occasional areas of hemorrhages, edema, hyperplasia and hyperkeratosis. The mites did not burrow beyond the epidermal region. The cut sections of mites were present in the superficial layers of the epidermis (Figure 8). No mite was observed in the skin scrapings of healthy, uninfected rabbits.

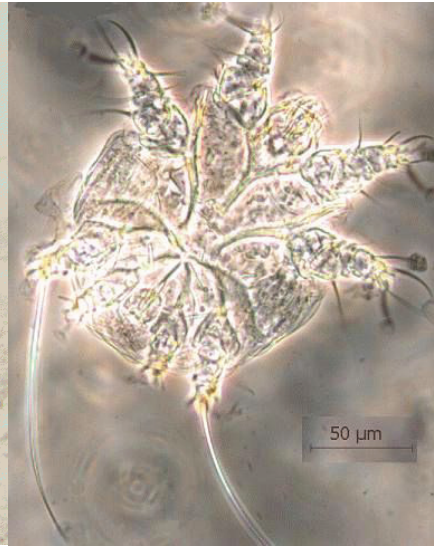

**Figure 4.** *N. cati* var. *cuniculi* egg containing larva

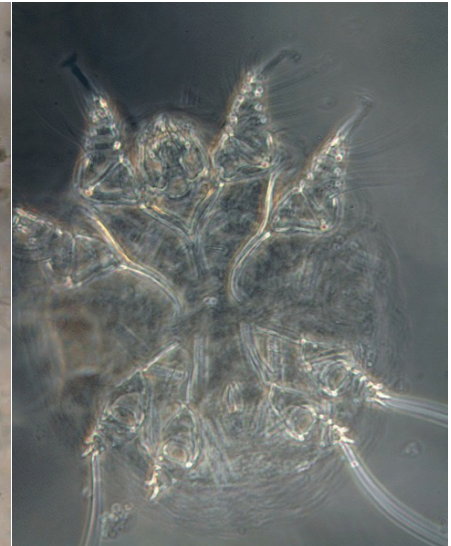




**Figure 5.** *N. cati* var. *cuniculi* larva showing two anterior and one posterior pair of legs.



**Figure 6.** *N. cati* var. *cuniculi* adult male characterized by long and unjointed pedicels with bell shaped suckers I, II & IV, epimeres and penis.



**Figure 7.** *N. cati* var. *cuniculi* adult female characterized by unjointed pedicels with bell shaped suckers I & II and dorsal anus.

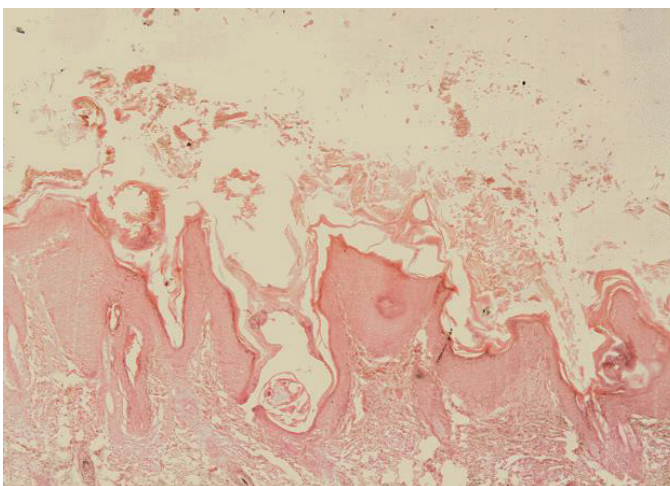
### Post-treatment

No adverse signs (nervous signs, depression, lethargy, diarrhea, blindness, abnormal behaviour, inflammation or pain at the site of injection) were observed after the administration of doramectin and diminazene acetate in any of the treated cases. The treatment resulted in progressively decreased frequency of itching. The animals stopped scratching completely within 5 days of the treatment. On day 7, skin scrapings were found negative for all the developmental stages of *N. cati* var. *cuniculi* except adult mites. Rabbits were negative for *T. evansi* from day 2 onwards as revealed by blood smear examination and mouse inoculation test. Hair started growing and the animals improved visibly in condition. Com-


plete cure was observed within 15 days of treatment as evidenced by complete lack of visually detectable lesions, absence of mites in skin scrapings, growth of hair and improvement in general condition of the animals (Figure 9). Up to 3 months after treatment, animals did not show any clinical signs and were parasitologically (blood and skin scraping examination) negative for the presence of mites and trypanosomes.

### Discussion

The rabbits used for the maintenance of strain of *T. evansi* may be sub-clinically infected with notoeridric mange. *T. evansi* infection may have made them prone to develop the clinical form of disease which



**Figure 8.** Section of skin showing hyperplasia and hyperkeratosis of epidermis along with cut sections of *N. cati* var. *cuniculi*.



**Figure 9.** Rabbit showing improvement 14 days after treatment.



was suspected from skin lesions and was easily diagnosed by skin scraping examination parasitologically. Notoedric mange has also been reported previously in other rabbits kept with the breeder (PAU, Ludhiana) and other parts of the city which were successfully treated with acaricides (Singla *et al*, 1996; Aulakh *et al*, 2003). Immunosuppression caused by *T. evansi* infections has been observed in cattle (Ikeme *et al*, 1984), Buffalo (Singla *et al*, 2001), goat (Sharma *et al*, 2000), pig (Holland *et al*, 2003) and guinea pig (Sarmah *et al*, 1997) from time to time by various workers. Flaring up of *T. evansi* infection due to immunosuppression caused by mange infection leading to mortality in pigs has also been observed (Gill *et al*, 1987).

The results of present studies that *N. cati* var. *cuniculi* mites did not burrow beyond superficial layers of epidermis in rabbits are confirmatory of the previous reports (Singla *et al*, 1996, Rajeswari *et al*, 1995) in rabbits. Pence and colleagues (Pence *et al*, 1982), however, reported occurrence of several notoedric mites in stratum corneum and a few in stratum germinativum of the bobcat.

In comparative trials of doramectin and ivermectin (Arends *et al*, 1999; Clymer *et al*, 1997), persistent efficacy of doramectin was found to be much longer on the basis of prevention of infestation and mite recovery. This may be due to its longer plasma half life than ivermectin and high concentration achieved in the skin to kill the mite present in the keratin layer of the skin (Goudie *et al*, 1993; Jones *et al*, 1993; Reinmeyer & Courteny, 2001). The long plasma life of doramectin is attributable to its oily formulation and its non-polar cyclohexyl group located at carbon 25 of the ivermectin ring (Wicks *et al*, 1993). Based on these factors when doramectin @ 400µg.kg<sup>-1</sup> body weight was injected to rabbits as a single dose, it was successful for bringing clinical and parasitological recovery from notoedric mange in rabbits infected with *T. evansi*. These results are similar to those reported by Delucchi & Castro (2000) against notoedric mange in cats. Voyvoda *et al* (2005) found the drug very effective against sarcoptic mange in angora rabbits.

One of the interesting observations during present studies was that all the rabbits which were not infected with *T. evansi* were healthy and clinically and parasitologically negative for notoedric mange during and after the experimentation. Perusal of available literature indicates that it appears to be

the first report of its kind due to the development of notoedric infection concurrent to trypanosomosis in rabbits with 100 percent recovery following a single dose of doramectin.

## References

- Arends JJ, TL Skogerboe & LK Ritzhanpt. Persistent efficacy of doramectin and ivermectin against experimental infestations of *Sarcoptes scabiei* var. *suis* in swine. *Vet. Parasitol.*, 1999, 82, 71-79.
- Aulakh GS, J Singh, LD Singla & N Singla. Pathology and therapy of natural notoedric acariasis in rabbits. *J. Vet. Parasitol.*, 2003, 17, 127-29.
- Bates PG, BA Groves, SA Courteney & GC Coles. Control of sheep scab (*Psoroptes ovis*) on artificially infested sheep with a single injection of doramectin. *Vet. Rec.*, 1995, 137, 491-21.
- Chakrabarti A. Human notoedric scabies from contact with cats infested with *Notoedres cati*. *Int. J. Dermatol.*, 1986, 25, 646-48.
- Chhabra C, DC Nauriyal, SS Khahra & SD Bhadwaj. Efficacy of moxidectin in notoedric mange in rabbits. *Indian J. Vet. Med.*, 1999, 19, 109.
- Clymer BC, TH Jones & ME McKenzie. Evaluation of therapeutic and protective efficacy of doramectin against *Psoroptes scabiei* in cattle. *Vet. Parasitol.*, 1997, 72, 79-89.
- Davies PR, MJ Moore & AM Pointon. Seasonability of sarcoptic mange in pigs in South Australia. *Australian Vet. J.*, 1991, 68, 390-92.
- Delucchi L & E Castro. Use of doramectin for the treatment of notoedric mange in five cats. *J. Am. Vet. Med. Assoc.*, 2000, 216, 215-16.
- Gill BS. Trypanosomes and trypanosomiasis of Indian livestock, 1st revised edition, Indian Council of Agricultural Research, New Delhi, 1991.
- Gill BS, J Singh, JS Gill & Kwatra MS. *Trypanosoma evansi* infection in pigs in India. *Vet. Rec.*, 1987, 120, 92.
- Goudie AC, NA Evans, KA Gration, BF Bishop, SP Gibson, KS Holdom, B Kaye, SR Wicks, D Lewis, AJ Weatherley & *et al*. Doramectin-a potent novel endectocide. *Vet. Parasitol.*, 1993, 49, 5-15.
- Holland WG, TT Do, NT Huong, TV Dung, NG Thanh, J Vercruysse & BM Goddeeris. The effect of *T. evansi* infection on pig performance and vaccination against classical swine fever. *Vet. Parasitol.*, 2003, 111, 115-23.
- Holmes PH. Vaccination against trypanosomes. In: *Vaccines against parasites*, AER Taylor & R Muller (eds.), 1<sup>st</sup> edn. Blackwell and Scientific Publications, Oxford, UK, 1980.
- Ikeme MM, AA Saharee, MZ Saad & R Koran. Effect of Experimental *Trypanosoma evansi* infection on cattle and subsequent response to haemorrhagic septicaemia vaccine. *Tropical Veterinaria*, 1984, 2, 61-67.



- Jagannath MS & S Yathiraj. Clinical evaluation of doramectin in the treatment of ectoparasites of canines. *Indian Vet. J.*, 1999, 76, 333-34.
- Jones RM, NB Logan, AJ Weatherley, AS Little & CD Smothers. Activity of doramectin against nematode endoparasites of cattle. *Vet. Parasitol.*, 1993, 49, 27-37.
- Logan NB, AJ Weatherley & RM Jones. Activity of doramectin against nematode and arthropod parasites of swine. *Vet. Parasitol.*, 1996, 66, 87-94.
- Mullen GR & Oconnor BM. Mites (Acari). In: *Medical and Veterinary Entomology*, G Mullen & L Durden (eds.), Academic Press, UK, 2002, 449-510.
- Muller GH, FW Kirk & DW Scot. *Small animal dermatology*, 3<sup>rd</sup> edn., W B Saunders, Co, Philadelphia, 1983, 331-52.
- Pence DB, FD Matthew & LA Windberg. Notoedric mange in the bobcat, *Felis rufus* from South Texas. *J. Wildlife Diseases*, 1982, 18, 47-50.
- Rajeswari YB, K Sattyannaran, MS Jagannath, U Venkatesh & YB Sumathi. Studies on histopathological changes of rabbit mange. *Parasitology and Applied Animal Biology*, 1995, 4, 97-98.
- Reinmeyer CR & CH Courteny. Antinematodal drugs. In: *Veterinary Pharmacology and Therapeutics*, HR Adams (ed.), State University Press, Ames, Iowa, 2001, 947-79.
- Sarmah PC, Y Bhattacharyulu & VB Yoshi. Effect of *Trypanosoma evansi* infection on the antibody response in guinea pigs vaccinated with haemorrhagic septicaemia oil adjuvant vaccine. *J. Vet. Parasitol.*, 1997, 11, 161-164.
- Sharma DK, PPS Chauhan & RD Agrawal. Interaction between *Trypanosoma evansi* and *Haemonchus contortus* infection in goats. *Proc. XI National Cong. Vet. Parasitol.*, 2000, 75-76.
- Singari NA, VR Kasaralika, B Shobhamani & DC Choudhuri. Notoedric mange in rabbits and its treatment with doramectin. *J. Vet. Parasitol.*, 2001, 15, 77-78.
- Singh V, RR Momin & HR Parsani. Therapeutic efficacy of doramectin against sarcoptic mange in camels. *J. Vet. Parasitol.*, 2001, 15, 75-76.
- Singla LD, PD Juyal & PP Gupta. Therapeutic trial of ivermectin against *Notoedres cati* var. *cuniculi* infection in rabbits. *Parasite*, 1996, 3, 87-89.
- Singla LD, PD Juyal, NS Sharma & A Singh. Responses to haemorrhagic septicaemia vaccination in *Trypanosoma evansi* infected buffalo-calves. *Proc. 10<sup>th</sup> Int. Conf. AITVM*, Copenhagen, Denmark, 20-23 August, 2001, 481 pp.
- Soulsby EJJ. *Helminths, Arthropoda and Protozoa of domestic animals*, 7<sup>th</sup> edn, Balliere Tindall, London, 1982.
- Voyvoda H, B Ulutas, H Eren, T Karagenc & G Bayramli. Use of doramectin for treatment of sarcoptic mange in five Angora rabbits. *Vet. Dermatol.*, 2005, 6, 285-88.
- Wicks SR, B Kaye, AJ Weatherly, D Lewis, E Davison, SP Gibson & DG Smith. Effect of formulation on the pharmacokinetic and efficacy of doramectin. *Vet. Parasitol.*, 1993, 49, 17-26.



